

OBSTRUCTIVE BILIARY CIRRHOSIS WITH ASCITES

Report of Two Cases

CHARLES H. BROWN, M.D.

and

ROBERT V. CHOISSER, M.D.*

Department of Gastroenterology

BILIARY cirrhosis has long been of interest in clinical and experimental medicine. Karsner¹ has classified biliary cirrhosis into two main categories, the first resulting from extrahepatic obstruction of the large bile ducts and the second caused by intrahepatic obstruction of the finer bile channels. The important feature in Karsner's classification is that the changes in the liver parenchyma are brought about by obstruction of the bile flow, whether the obstruction lies outside the liver in the large bile ducts or within the liver in finer biliary channels. Both give signs of obstructive jaundice when examined by liver function tests and bile circulation studies. This is in contradistinction to Laennec's cirrhosis or hepatitis, diseases primarily effecting the parenchymal cell of the liver. In the present discussion, we are concerned only with the liver changes caused by obstruction in the large extrahepatic bile ducts.

Experimentally, changes typical of biliary cirrhosis have been produced in animals. Rous and Larimore² reported that ligation of the common duct in rabbits resulted in cirrhosis of an interlobular type with many new bile ducts, simple atrophy of the parenchyma of the liver, and a dwindling in the size of the lobule. By ligation of smaller ducts they were able to produce a pure monolobular cirrhosis. They reported similar changes in the dog. Cameron and Oakley³ found that occlusion of the common bile duct in rats, guinea pigs, and rabbits resulted in comparable findings with bile duct hyperplasia, dilatation of the bile passages, the growth of new bile ducts, atrophy, and degeneration and regeneration of liver cells. They observed "hyaline" degeneration of liver cell columns. MacMahon, Lawrence and Maddock⁴ studied the changes in the liver of guinea pigs, induced by ligation of the common bile duct. They state, "In the early stages, bile stasis, necrosis and regeneration of individual liver cells, edema, and infiltration of the portal areas are the most prominent features. Later there is an apparent increase in the number of bile ducts; the portal connective tissue is increased." Stewart and Lieber⁵ reported similar observations produced by ligation of the common duct of the cat, and noted a remarkable parallelism between the results of this experiment and the lesions seen clinically in man. It is obvious from investigative work that obstruction to bile flow results in profound and usually characteristic changes in the liver.

*Now practicing in Washington, D. C.

Alterations associated clinically with complete or intermittent and partial occlusion of the common bile duct also have been reported. MacMahon and Mallory⁶ studied 20 cases of obstructive cirrhosis in adults and 10 in children and found changes similar to those observed in the experimental animal. They stated: "The early stage in all cases is characterized by a dilatation of the ducts with bile stasis within the lobule. This is followed by an elongation of the terminal ducts associated with an appreciable increase in portal connective tissue, commonly accompanied with a moderate cellular infiltration into the portal areas and the appearance of regressive changes in the liver cells in the central zones of the lobule." Lieber and Stewart⁷ discussed the changes caused by obstruction to the common bile duct by carcinoma of the pancreas; they reported that the biliary conducting system undergoes a tremendous volumetric increase, the process extending to the small branches. The canaliculi are distended with bile thrombi, and bile pigment may be present in the cells of the central portion of the lobule. Degenerative and necrotic changes involving the hepatic cells about the central vein may occur. The intrahepatic ducts elongate and become tortuous. They found a characteristic and pronounced deposition of connective tissue which is interlobular, intralobular and even perilobular. Gibson and Robertson⁸ found similar changes in 21 of 244 patients having died of obstructive jaundice. The characteristic features again were moderate to intense increase in portal connective tissue with intralobular extension, evidence of parenchymal degeneration, bile thrombi, an increase in interlobular bile ducts, and collections of lymphocytes or polymorphonuclear leukocytes. They emphasized the presence of parenchymal degeneration and regeneration and fibrosis. In none of these patients did the past history suggest antecedent liver disease, and these authors attributed the changes in the liver to obstruction of the bile flow. From a clinical viewpoint, obstruction to the bile flow can cause profound changes in the liver.

Ascites, when coexistent in any form of cirrhosis, is always considered a late sign and evidence of severe fibrosis and portal hypertension. Its presence, however, is particularly infrequent in biliary cirrhosis. Hanot, in his original description of intrahepatic biliary cirrhosis, did not include ascites as one of the findings. More recently, Dauphinee and Sinclair⁹ reported 4 patients with intrahepatic biliary cirrhosis and ascites. MacMahon and Mallory,⁶ in reviewing 30 cases of extrahepatic obstructive biliary cirrhosis, described one ascitic patient. Gibson and Robertson,⁸ in their series of 244 cases of obstructive jaundice, found 6 patients with concomitant ascites; one of these had carcinomatosis of the peritoneum. Snell, Greene, and Rowntree¹⁰ described ascites, extensive collateral circulation, and monolobular hepatic fibrosis in 2 dogs, occurring after prolonged ligation of the common duct. Ascites is relatively frequent in patients with Laennec's cirrhosis and in severe hepatitis. Conversely, it infrequently accompanies obstructive jaundice and extrahepatic biliary cirrhosis; its presence may considerably confuse the clinical picture and make the correct diagnosis difficult. The 2 patients subsequently reported, who had extrahepatic obstructive cirrhosis associated with ascites, were of unusual clinical interest.

Case Reports

Case 1. A 69 year old woman was admitted to the hospital in November 1950 with a history of swelling of the abdomen apparently for 3 weeks, jaundice for 4 weeks, and repeated attacks of chills and fever occurring every 3 weeks and lasting 1 to 2 days for the previous 6 months. Severe pruritus, light stools and dark urine had been present since the onset of jaundice. She had lost 38 pounds in the past 15 months. She had been observed at the Clinic in November 1949, at which time she complained of mild indigestion. Complete physical examination, laboratory studies and gastrointestinal roentgenologic examination were all entirely negative except for nonfilling of the gallbladder. She was seen again in May 1950. She had lost a little weight but was otherwise apparently well. Her past history was noncontributory.

On physical examination in November she was emaciated and icteric. The liver was enlarged 7 to 8 cm. in the midclavicular line and the abdomen was distended; a fluid wave and shifting dullness were present. Laboratory examinations were as follows: Blood count normal. Urine was positive for bile, as were the stools. Alkaline phosphatase was 26.5, serum bilirubin 8.0 with a direct reaction; the cephalin cholesterol flocculation test was negative, and the thymol turbidity was 2.0. Serum albumin was 3.1 and globulin 2.9.

A paracentesis was performed and 1300 cc. of ascitic fluid was removed; this was studied for tumor cells but none were found. Roentgenologic examination of the stomach and colon were negative except for the presence of a large duodenal diverticulum. During the next few days, the patient's icteric index fluctuated between 25 and 40 and the stools were intermittently negative for bile. A needle biopsy of the liver was obtained, using the Vim-Silverman needle, and the specimen showed definite bile stasis and severe biliary cirrhosis (fig. 1).

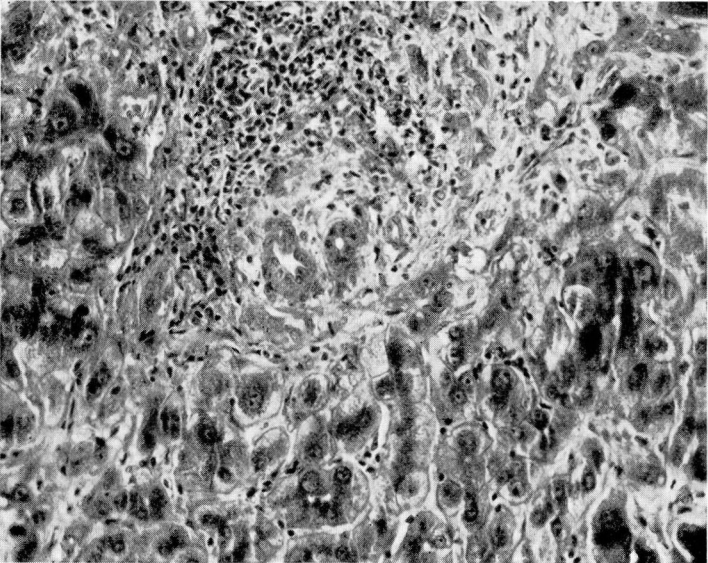
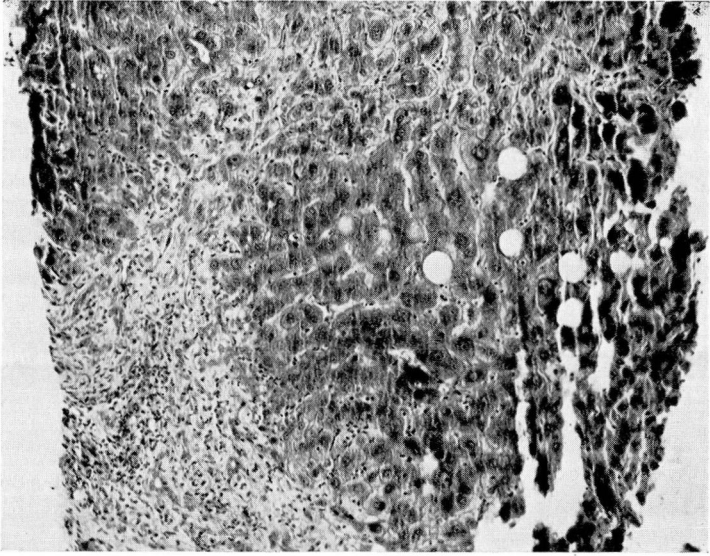
An exploration was performed on the fourteenth day to establish the cause of the obstruction and to relieve it. The gallbladder and common duct were found to be greatly dilated and thickened and a large calculus was palpated in the ampula of Vater. The liver was finely nodular and the spleen moderately enlarged with a dilated splenic vein. The calculus was removed and a cholangiogram of the patient on the operating table showed no additional stones. A T-tube was left in the common duct.

Following surgery, the patient's jaundice rapidly subsided and her postoperative course was uneventful. Two months subsequent to operation she was neither jaundiced, nor ascitic; a cholangiogram still showed some dilatation of the common duct, but no evidence of obstruction. Another cholangiogram taken 2 months later revealed no change in the patient's condition and the T-tube was removed. At that time her icteric index was 6, and 3 per cent retention of the bromsulfalein dye was present in 30 minutes (5 mg. of dye per kilo body weight). She was last examined on May 23, at which time she was symptom-free and had gained 39 pounds. There was no evidence of jaundice or ascites. The liver edge was barely palpable at the costal margin. Liver function studies were entirely normal. Bromsulfalein liver function test showed 4 per cent retention of the dye in 30 minutes, the cephalin flocculation test was negative, the thymol turbidity was 2.0; the alkaline phosphatase was now 5 units, serum albumin was 4.3 and globulin 3.0.

Comment

This patient presented a complicated diagnostic problem, and surgery was recommended only after lengthy consideration of her condition. The previous observation of a nonfunctioning gallbladder, the history of chills and fever,

(a)



(b)

FIG. 1. Needle biopsy of the liver in case 1 (common duct stone). (a) Increase in the connective tissue in the portal areas; some increase in number of bile ducts. The fibrosis is fairly sharply demarcated, and the liver cells appear relatively well preserved with little distortion of the liver columns themselves ($\times 100$). (b) Portal fibrosis is evident, and there is some increase in bile ducts. There is an infiltration of lymphocytes present; this has been reported in common duct ligation in animals but is uncommon in man ($\times 200$).

and the evidence from laboratory studies were all suggestive of partial obstruction of the common duct. The fluctuating icteric index, elevated alkaline phosphatase, the intermittent appearance of bile in the stool, negative cephalin flocculation and thymol turbidity tests were all compatible with partial biliary obstruction, and a preoperative diagnosis of a common duct stone was made. The presence of ascites was confusing as this condition infrequently accompanies obstructive jaundice, even when complicated by biliary cirrhosis. The surgeon declined to operate, as he believed the ascites indicated severe Laennec's cirrhosis. Our results¹¹ on liver biopsy have previously been recorded and this experience proved most helpful in diagnosing the case. The needle biopsy specimen showed severe bile stasis and biliary cirrhosis. On the basis of this evidence the surgeon was persuaded to operate. Otherwise the patient's condition necessarily would have been treated as Laennec's cirrhosis, with an inevitably fatal outcome. This case illustrates the fact that needle biopsy of the liver may be extremely useful in the diagnosis of obscure liver disease, and in differentiating obstructive from hepatic jaundice.

This case also shows, as have the experimental and clinical studies already cited, that partial obstruction of the common bile duct can cause profound changes in the liver, and in this instance ascites. While seldom associated with obstructive jaundice, ascites may be produced by the severe changes in the liver and the biliary cirrhosis which develop secondary to the biliary obstruc-

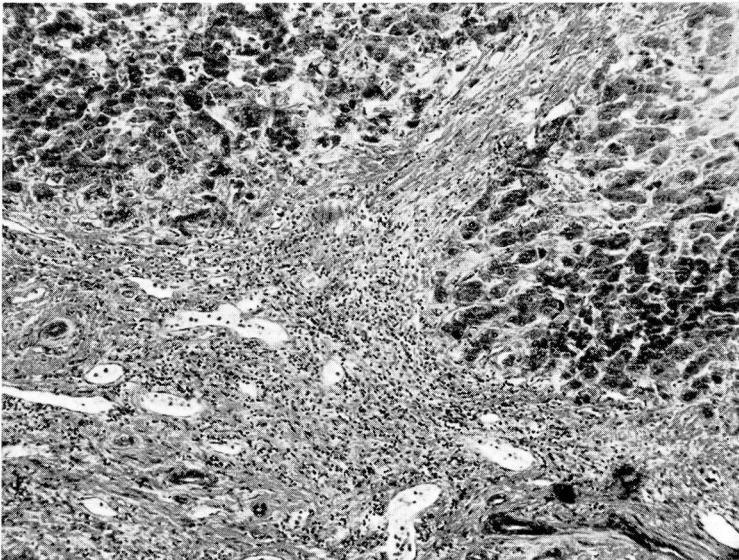


FIG. 2. Section of liver; autopsy specimen; carcinoma of the common bile duct. Portal fibrosis with increase in bile ducts is evident. There is extension of the fibrosis perilobularly, and also between the liver columns. The latter is unusual in biliary cirrhosis and probably occurred because of the long duration of obstruction. Many bile thrombi were present ($\times 70$).

tion. One should not hastily diagnose hepatic jaundice (Laennec's cirrhosis or hepatitis) because of the presence of ascites. Infrequently it may be a manifestation of severe biliary cirrhosis due, secondarily, to obstruction of the common bile duct.

Of further interest is the fact that, once the obstruction in the common bile duct was relieved, the jaundice and ascites rapidly disappeared. Remarkable improvement in biliary cirrhosis in experimental animals has also been reported when the obstruction in the common bile duct is removed. A good prognosis, as illustrated by this case, can be given patients with severe biliary cirrhosis, if that cirrhosis is caused by obstruction of the common bile duct and the obstruction is surgically relieved.

Case 2. A 39 year old woman was first seen in the Clinic in April 1942 with a history of a cholecystectomy performed in 1940, followed by a persistent fistula which necessitated an exploration of the common duct in July 1941. The fistula finally closed in November 1941. For a month prior to admission to the Clinic, jaundice, pruritus, clay-colored stools and periodic diarrhea had been present. Positive physical findings on admission were pronounced icterus, an enlargement of the left ventricle with a grade IV apical rumbling diastolic murmur and a grade III apical systolic murmur consistent with rheumatic heart disease. Laboratory examinations were essentially normal except for an icteric index of 75. At operation no common duct could be identified in the dense mass of adhesions, and a catheter was left in the stump of the hepatic ducts.

Following surgery the jaundice disappeared rapidly, but on the tenth postoperative day the patient vomited a large amount of blood. Her prothrombin time was 50 per cent of normal but returned to 100 per cent following two transfusions; she then made satisfactory progress. The stools became brown and the T-tube was removed in July, 2 months after surgery.

In December 1942 there was a recurrence of jaundice and clay-colored stools, and she was reoperated upon in an attempt to insert a vitallium tube in the hepatic ducts. However, the ducts were too small and another catheter was inserted. This measure relieved her jaundice until January 1944 when the jaundice recurred after the tube had pulled out. A new tube was inserted which, while it drained bile, never completely relieved her jaundice. In May 1945 she was readmitted because of bleeding about the tube, and physical examination for the first time showed enlargement of the liver and spleen. Her icteric index was 25. She was given several blood transfusions, and discharged on an outpatient basis. The patient was seen in 1946, 1947 and 1948 and reported occasional episodes of bleeding about the tube and mild fluctuating jaundice. In June 1948 there were several occurrences of chills and fever associated with fluctuating jaundice and clay-colored stools.

Because of loss of weight and repeated episodes of chills and fever which accompanied the jaundice, she was again admitted to the hospital in November 1949. Physical examination once more showed enlargement of the liver and spleen and, for the first time, ascites. At operation, in addition to massive adhesions, the liver was found to be finely nodular and the spleen greatly enlarged. At this time a tube was connected to the stump of the hepatic duct and through the duodenum. Postoperatively the jaundice subsided and the patient progressed satisfactorily. An x-ray of the stomach revealed a small gastric ulcer on the lesser curvature.

In March 1950 her icteric index was 68, serum albumin was 2.5 and globulin 4.7. The thymol turbidity was elevated to 7 units and the cephalin cholesterol flocculation test 4 plus. The patient was seen again in September 1950 at which time the jaundice

and ascites had increased, and she had developed edema of the legs. There was little or no pulmonary congestion, but digitalis was administered and a low salt diet prescribed. The peripheral edema subsided but there was no diminution of the ascites.

In December 1950 the patient was admitted for the last time because of recurrence of jaundice and edema of the legs. Physical examination revealed pronounced icterus, noticeable enlargement of the liver and spleen, and moderate ascites, but no evidence of pulmonary congestion. The icteric index was 100, thymol 5.5. units, and prothrombin time 68 per cent. Exploration was undertaken for the fourth time in the Cleveland Clinic Hospital and another polyethylene tube was inserted into a small hepatic duct that was observed to drain bile. On the sixth postoperative day she suddenly vomited a large quantity of blood, went into irrecoverable shock, and died.

Autopsy examination revealed multiple superficial gastric ulcerations as the cause of the massive gastrointestinal hemorrhage. The heart weighed 314 Gm. and showed stenosis of the mitral valve. The spleen weighed 800 Gm. and was soft and flabby. The liver, which weighed 1,500 Gm., was dark green in color, was finely granular and studded with unusually small nodules. Microscopic examination of the liver disclosed definite peribulbar fibrosis with dense lymphocytic infiltration, proliferation of the bile ducts, and abundant green-brown pigment within the liver cells and sinusoids.

Comment

This case illustrates characteristically the protracted and usually fatal course of patients with stricture of the common duct. The circumstance is particularly unfortunate because it is possible that, had the initial surgery been uncomplicated and had cholangiography been employed at that time, she would have recovered from the biliary tract disease. Patients with strictures of the common duct, even when the obstruction is relieved by a vitallium tube or an anastomotic operation, are likely to develop repeated attacks of cholangitis and subsequently fatal biliary cirrhosis.

This case also emphasized the profound effect of obstruction of the common bile duct upon the liver. That the damage was severe is demonstrated by the enlargement of the liver and spleen, the development of ascites, the reversal of the albumin globulin ratio and the positive flocculation tests. The latter two developments indicate extreme damage to the parenchymal cells of the liver.

A third point of interest concerning this case is the fact that gastric ulceration was discovered almost 3 years prior to the death of the patient while focal gastric ulceration with hemorrhage was the immediate cause.

Markowitz¹² noted that, in animals, total exclusion of bile from the intestines was a common cause of typical chronic peptic ulcers.

Discussion

The development of ascites is rare in obstructive biliary cirrhosis and, as in portal cirrhosis, the mechanism is thought to be largely a combination of two factors, (1) portal hypertension, and (2) decreased plasma colloid osmotic pressure. Higgins et al¹³ studied 19 patients with ascites in a series of 35 cases of chronic and subacute hepatitis, and found that ascites seldom was present when the colloidal osmotic pressure of the plasma remained within normal

limits. They assumed that the dependence of the formation of ascites on a low level of plasma proteins was a useful point in diagnosis. Ralli et al¹⁴ observed a third factor in the formation of ascites when they demonstrated that the urine of effected patients had a greater antidiuretic effect when injected into hydrated rats than urine from nonascitic or normal persons. They believed that this blocking effect indicated failure of the liver to destroy some antidiuretic principle, probably secreted by the posterior pituitary gland. Whether or not a patient with liver disease develops ascites, may depend on the combination of these three factors.

The course of the 2 patients, one terminating in death and the other in recovery, demonstrates the importance of recognizing the presence of obstructive biliary cirrhosis and eliminating the causative factor. The significance of an accurate diagnosis cannot be overemphasized. White¹⁵ suggested, after having reviewed 500 cases of jaundice, that surgery be avoided in cases of acute icterus with brown stools; thus the danger of operating on a patient with acute hepatitis will be eliminated. Although the usual mortality of gallbladder surgery is 2 to 5 per cent, his series showed 35 per cent in patients with cirrhosis and 100 per cent in patients with severe acute hepatitis who were subjected to operation. Surgery on a patient with Laennec's cirrhosis or with acute hepatitis may precipitate death, while lack of surgery in a patient with obstructive jaundice caused by a common duct stone, as in case 1, may be equally fatal. Liver biopsy, showing bile stasis and biliary cirrhosis as in case 1, may be of considerable help in the decision as to whether a patient with apparently obstructive jaundice should be subjected to operation.

Summary

Two unusual cases of obstructive biliary cirrhosis with ascites have been presented. In the first case, the biliary cirrhosis and ascites were secondary to a common duct stone, and the patient was cured following removal of the stone. Liver biopsy was especially helpful in the diagnosis and in the decision to operate. The second case was due to stricture of the common duct and illustrates the frequently relentless course and fatal termination in these patients despite repeated attempts at reconstruction of the common duct and re-establishment of biliary drainage. Both cases demonstrate the severe changes in the liver that can result from obstruction of the extrahepatic bile ducts.

References

1. Karsner, H. T.: Morphology and pathogenesis of hepatic cirrhosis. *Am. J. Clin. Path.* 13:569 (Nov.) 1943.
2. Rous, P. and Larimore, L. D.: The biliary factor in liver lesions. *J. Exper. M.* 32:249, 1920.
3. Cameron, G. R. and Oakley, C. L.: Ligation of common bile duct. *J. Path. and Bact.* 35:769 (Sept.) 1932.
4. MacMahon, H. E., Lawrence, J. S. and Maddock, S. J.: Experimental obstructive cirrhosis. *Am. J. Path.* 5:631 (Nov.) 1929.

5. Stewart, H. L. and Lieber, M. M.: Ligation of common bile duct in cat. *Arch. Path.* **19**:34 (Jan.) 1935.
6. MacMahon, H. E. and Mallory, F. B.: Obstructive cirrhosis. *Am. J. Path.* **5**:645 (Nov.) 1929.
7. Lieber, M. M. and Stewart, H. L.: Hepatic and bile duct changes from obstruction of common bile duct due to pancreatic carcinoma. *Arch. Path.* **17**:362 (March) 1934.
8. Gibson, W. R. and Robertson, H. E.: So-called biliary cirrhosis. *Arch. Path.* **28**:37 (July) 1939.
9. Dauphinee, J. A. and Sinclair, J. C.: Primary biliary cirrhosis. *Canad. M.A.J.* **61**:1 (July) 1949.
10. Snell, A. M., Greene, C. H. and Rowntree, L. G.: Diseases of liver; further studies in experimental obstructive jaundice. *Arch. Int. Med.* **40**:471 (Oct.) 1927.
11. Rossmiller, H. R., Brown, C. H. and Whitman, J. F.: Needle biopsy of liver. *Cleveland Clin. Quart.* **17**:64 (April) 1950.
12. Markowitz, J.: *Experimental Surgery*, ed. 2. Baltimore, Williams and Wilkins Company, 1949, p. 546.
13. Higgins, G., and others: Ascites in chronic disease of liver. *Quart. J. Med.* **16**:263 (Oct.) 1947.
14. Ralli, E. P., Robson, J. S., Clarke, D. H. and Hoagland, C. L.: Factors influencing ascites in patients with cirrhosis of liver. *J. Clin. Investigation* **24**:316 (May) 1945.
15. White, F. W.: Study of errors in diagnosis of jaundice. *New England J. Med.* **229**:997 (Dec. 30) 1943.