

THE TREATMENT OF CHRONIC ULCERATIVE COLITIS

GEORGE CRILE, JR., M.D. and R. B. TURNBULL, JR., M.D.

Department of Surgery

Results of Conservative Therapy

ALTHOUGH most patients with chronic ulcerative colitis do well without operation, about 20 per cent suffer from severe and intractable forms of the disease and do not improve on medical treatment. Many of these persons die of the disease or are incapacitated, both economically and socially. Since colectomy rehabilitates these patients and prevents most of the fatal complications of the disease, serious consideration must be given to extending the indications for surgical intervention.

Prior to the development of the modern type of ileostomy appliance, the life of the patient who had undergone an ileostomy was not a pleasant one. The appliances were not leakproof, many were malodorous, and provision was not made for protecting the skin from the irritating discharges of the ileostomy. Moreover, the technic and postoperative management of ileostomy and of colectomy had not been developed, the mortality rate was high among surgical patients, and often the stomas were so placed that they could not be fitted with a satisfactory appliance. For these reasons, gastroenterologists in the past seldom advised ileostomy or colectomy for patients with ulcerative colitis.

Results of Simultaneous Ileostomy and Subtotal Colectomy in the Treatment of Chronic Ulcerative Colitis

In the past 5 years advances in the technic of ileostomy and colectomy and improvements in the preoperative and postoperative care of patients with ulcerative colitis have resulted in a striking reduction in both morbidity and mortality after operation. For example, in the past 2 years (September 1949—September 1951) we have performed subtotal colectomy with simultaneous ileostomy 22 times as an elective procedure for chronic ulcerative colitis and removed the lower sigmoid colon and rectal stump as a secondary operation in 27 cases without a fatality. Rehabilitation of the patient occurred promptly after removal of the colon as exemplified by one patient who gained 30 pounds in the first 30 days, and no patient has failed to make a satisfactory social adjustment following the ileostomy.

Results of Conservative Treatment of Acute Toxic Ulcerative Colitis

The most dangerous type of ulcerative colitis is the rare acute, toxic variety which constitutes only 5 per cent of all cases of ulcerative colitis. Toxicity may be the first manifestation of the disease or may be an exacerbation of a chronic

colitis. In either case, the mortality rate is exceedingly high either following ileostomy alone or with conventional medical treatment.^{1,2}

The true mortality rate in patients with acute toxic ulcerative colitis has not always been appreciated, because many of these patients are discharged from the hospital improved only to die at home as a result of an acute exacerbation of the disease. Thus, although only 36 per cent² of the patients with acute toxic ulcerative colitis died at the time of the first hospitalization, we found that, by the time 2 to 5 years had passed, the mortality had risen to 68 per cent, and little difference was apparent in the over-all mortality whether the patients had been treated by ileostomy or by conservative measures. Moreover only 13 per cent of the patients receiving medical treatment were rehabilitated socially and economically.

Rationale of Subtotal Colectomy with Simultaneous Ileostomy in Acute Toxic Ulcerative Colitis

Frequently the statement has been made that a patient with acute toxic ulcerative colitis is too ill to withstand ileostomy. Often this statement is correct because, when the strain of anesthetic and operation and the inevitable disturbances of nutrition and electrolyte balance which accompany ileostomy are superimposed on the anemia, sepsis, and metabolic exhaustion from which the patient is already suffering, the result may be fatal. But if at the same time it is possible to remove the colon which is the source of the anemia and sepsis, the patient has a better chance of withstanding operation and recovering good health. Our attitude toward the patient with acute toxic ulcerative colitis, therefore, has undergone an "about face," and we no longer say that a patient is too sick to be operated upon; rather we agree with Ferguson³ who said "the patients are too sick **not** to be operated upon."

The operation which is performed for patients with acute toxic ulcerative colitis should not be the minimal operation of ileostomy, which may cause the least shock and which also results in the least improvement, but should be the maximum operation of subtotal colectomy with ileostomy, which causes prompt improvement in the general condition of the patient. It is important to remember that patients with acute toxic ulcerative colitis do not often die as a result of their operations but as a result of their disease. Even extensive operations are tolerated well provided that the disease is eradicated.

Patients with primary acute toxic ulcerative colitis often have colons that are atonic and distended due to the invasion and destruction of both mucosal and muscular coats of the bowel (fig. 1). This distention is a grave prognostic sign and often signifies impending perforation. These colons are, in effect, nothing more than a serosal sac filled with feces, pus and blood and lined only with shaggy ulcers interspersed by ragged mucosa. The physiologic effect of such a colon is comparable to that of an extensive third degree burn covered with a fecal poultice. After colectomy the patient's recovery from the effects of sepsis is often as prompt and dramatic as the recovery which follows the cleansing and grafting of a badly infected third degree burn of comparable area (fig. 2).

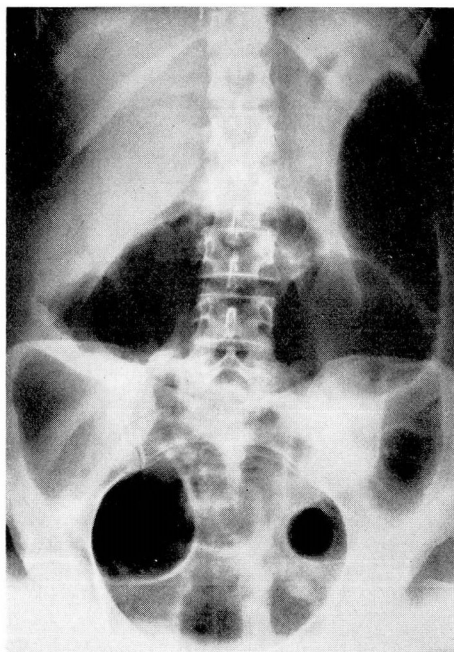


FIG. 1. Toxic fulminating ulcerative colitis. Flat film of abdomen showing dilatation of colon at height of toxicity.

Until the colon is removed, there is a continuous loss of blood and protein into the lumen of the bowel and a continuous absorption of its toxic contents. Pronounced inflammatory changes are present, blood vessels are thrombosed, and there is necrosis of mucosa with deep ulceration associated with multiple localized areas of peritonitis. Unless the bowel is removed, the ulceration may progress to perforation and fatal peritonitis.

In acute toxic colitis, ileostomy alone does little more than slightly retard this process (fig. 3). After ileostomy, fever, toxemia, bacteremia and a tendency to develop thromboembolic phenomena may persist. When the colon is removed, however, the source of these difficulties is eradicated; the blood and serum protein loss is checked, fever and toxemia subside and the serum proteins rise rapidly. Evidence of vitamin deficiency disappears, cutaneous ulcers heal and arthritis subsides. All of these results tend to occur with dramatic suddenness after colectomy, whereas after ileostomy alone there may be little or no alteration in the clinical picture, or the improvement may be so slow that it must be measured in weeks or months instead of days.

Results of Subtotal Colectomy with Simultaneous Ileostomy in Acute Toxic Ulcerative Colitis

During the past 2 years (September 1949—September 1951) we have performed 10 ileostomies with simultaneous subtotal colectomies in the treatment

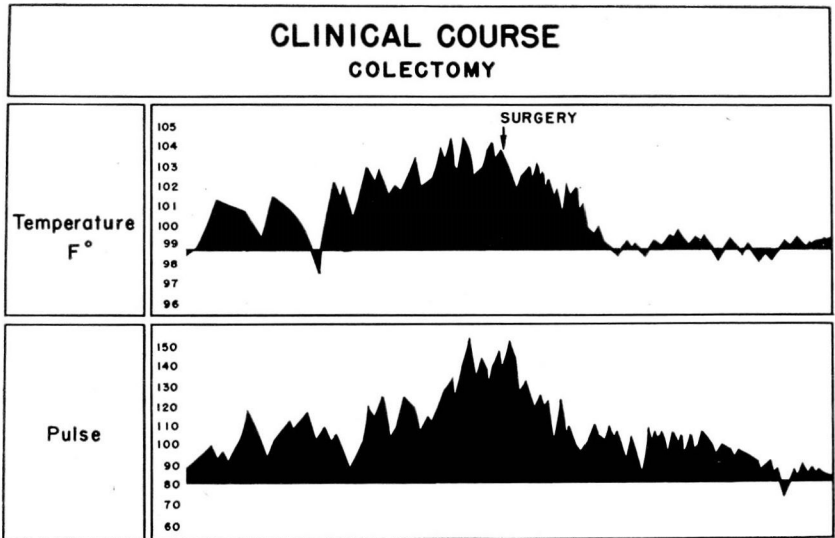


FIG. 2

of all patients in whom the diagnosis of acute toxic ulcerative colitis was made. Operation was not withheld because of the seriousness of the disease or the patient's poor condition. The 2 patients who died were moribund at the time of operation. One (aged 62) had had numerous perforations of the colon and the other was in the terminal stages of toxemia with massive edema and a serum albumin of 0.6 mg. per cent. The other patients in this series have improved satisfactorily.

The median day of discharge was the thirteenth postoperative day, a noteworthy advancement when compared with the former method of treatment in which ileostomy followed by a stage colectomy required an average of 2 months hospitalization with many months of convalescent care at home between stages. The patients subjected to ileostomy and simultaneous colectomy are now completely rehabilitated and have returned to their former economic and social activities. Several patients were able to return to work within a few weeks subsequent to operation.

Although sufficient time has not yet elapsed to enable us to evaluate the mortality rate over a 5 year period, there is no reason to believe that these patients are any longer in grave danger of dying as a result of their disease. Since the mortality in a similar group of patients managed by more conservative means was 60 per cent, and since by medical treatment we had been able to rehabilitate economically and socially only 13 per cent of the patients of this particular group, it is apparent that simultaneous ileostomy with colectomy is both safer and more effective than conservative measures, including ileostomy alone.

Relationship of Chronic Ulcerative Colitis to Carcinoma of the Colon

Many patients with longstanding ulcerative colitis whose colons are not removed develop highly malignant carcinomas of the colon. In Gleckler's and Brown's⁴ series, reported from this clinic, carcinoma was found in nearly 10 per cent of the patients with ulcerative colitis who were subjected to colectomy and, in 4 of the 12 cases reported, the carcinoma developed after ileostomy had been performed. It is, therefore, apparent that ileostomy alone does not protect against the development of cancer, and that this fatal complication is a definite menace to patients who have protracted ulcerative colitis.

Discussion

If the ileostomy is properly made and placed, the modern type of ileostomy appliance fits snugly without leakage and the skin is not irritated by the ileal content. We have invariably left the rectum in place at the time of the subtotal colectomy and have told the patients that, should a medical cure for ulcerative colitis be found, the continuity of the intestinal tract could be re-established; however no patient in this consecutive series of 32 cases has complained of the ileostomy or requested re-establishment of intestinal continuity. After the patients are adjusted following an ileostomy, the possibility of a carcinoma developing in the rectal stump is explained to them and they usually will permit removal of the rectum although recognizing the fact that the ileostomy becomes permanent.

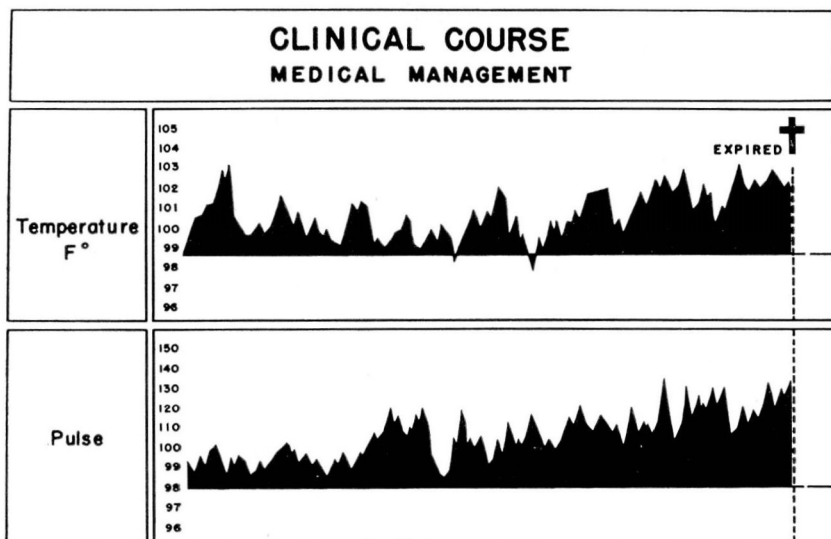


FIG. 3

Since multiple stage operations for ulcerative colitis are complicated by contamination from the ileostomy and the exteriorized stump of the colon, they are attended by a higher incidence of wound infection and postoperative morbidity than a one stage procedure. Multiple stage operations require several times as much hospitalization as the single stage procedure. The patient's recovery from the disease and his return to normal social and economic life are much more rapid following simultaneous ileostomy and colectomy than following stage operations.

Although economic factors are important, the main consideration is saving the patient's life. The danger in the toxic form of colitis is not from the operation but from the disease, and the sooner the patient's disease is eradicated the safer he becomes. For these reasons we believe that one stage ileostomy and colectomy is the preferred treatment for acute toxic ulcerative colitis.

Cortisone and ACTH have been used in ulcerative colitis and appear to benefit the patient symptomatically as long as they are given. It is possible that these agents may be of some value in preparing desperately ill patients for operation. In one case in this series the improvement was striking and operation appeared to be made more safe by its use. In a second case, however, no benefit was observed and, in a third not included in this series in which no operation was performed because the diagnosis of ulcerative colitis was not made before autopsy, a fatal perforation followed the use of cortisone. Since similar experience has been reported by others we do not believe that these agents should be used except in the immediate preoperative period in an attempt to ameliorate the condition of desperately ill patients. Although milder forms of the disease should be given a trial on conventional medical treatment, removal of the colon as completely and as quickly as possible appears to be the safest method of treating patients with acute toxic or severe chronic ulcerative colitis. We do not believe that ileostomy alone is indicated in the treatment of this disease.

Summary

1. Prolonged conservative treatment of intractable ulcerative colitis is both dangerous and unsatisfactory.
2. The mortality rate from cancer of the colon developing in patients with intractable ulcerative colitis exceeds the risk of colectomy.
3. One stage colectomy with simultaneous ileostomy is the safest and most effective treatment for acute toxic ulcerative colitis, or for the severe intractable chronic forms of the disease.
4. There is no place for ileostomy alone in the treatment of ulcerative colitis.
5. In acute toxic ulcerative colitis, the mortality rate among patients having one stage ileostomies and colectomies is only one-third that of those receiving medical treatment or having ileostomies alone.
6. In chronic, nontoxic forms of ulcerative colitis, there has been no mortality in a consecutive series of 22 elective one stage ileostomies and colectomies followed in most cases by removal of the rectal stump.

7. Since a properly made and placed ileostomy fitted with a modern type of appliance enables the patients to make satisfactory social and economic adjustments, there is no longer any reason to deny the benefits of one stage ileostomy and colectomy to those whose lives are threatened or whose social and economic activities are limited by ulcerative colitis.

References

1. Brown, C. H., Gleckler, W. J. and Jones, T. E.: Surgical treatment of chronic nonspecific ulcerative colitis. *Gastroenterology* **14**:465 (April) 1950.
2. Crile, George, Jr. and Thomas, C. Y.: Treatment of acute toxic ulcerative colitis. *Gastroenterology* (In press).
3. Ferguson, L. K. and Stevens, L. W.: Surgery of complications of ulcerative colitis. *Gastroenterology* **11**:640 (Nov.) 1948.
4. Gleckler, W. J. and Brown, C. H.: Carcinoma of colon complicating chronic ulcerative colitis. *Gastroenterology* **14**:455 (April) 1950.