

THE DIAGNOSIS AND SURGICAL TREATMENT OF HYDRONEPHROSIS DUE TO ABERRANT ARTERY

WILLIAM J. ENGEL, M.D.,
Department of Urology

A VARIETY of lesions may produce upper urinary tract obstruction and if it occurs over a long period of time the back pressure produces a hydronephrosis. The obstruction produced by an aberrant artery is of this type and these cases constitute an interesting group whose symptomatology should be recognized in the differential diagnosis of any pain in the flank or abdomen. Its etiology lies in a congenital failure. The kidney in its embryologic ascent derives its blood supply from successively higher levels as it rises from the pelvis to its final level. As new arteries take over the nutrition of the organ, the previous ones become obliterated until, normally, a single artery remains as the blood supply to the kidney. If one of the previous arteries fails to become obliterated, this one persists and is termed an aberrant artery.

It has been estimated that aberrant vessels are present in 20 per cent of all persons, 80 per cent going to the upper pole of the kidney and 20 per cent to the lower pole. We are not concerned with the former as they are not troublesome, but 80 per cent of all aberrant arteries to the lower pole produces obstruction to the ureter with a resultant hydronephrosis (fig. 1).

Experience with these cases also has shown that these arteries always are associated with fibrous bands which cause the ureter to be closely adherent to the artery; this, I believe, is an important essential to the production of obstruction by creating a fixed point at the ureteropelvic junction. This acts first by impeding normal ureteral peristalsis and secondly by producing angulation of the ureter in the erect posture when the kidney normally tends to drop. A clinical study of these cases leads us to believe that the former mechanism is more important.

That the process is extremely slow and insidious is indicated by the fact that symptoms seldom develop before the age of 15, and a diagnosis is not made in the majority of cases until patients are 20 to 30 years of age. Of 52 patients studied, 30 per cent had symptoms for 10 or more years and 55 per cent for at least 3 years before a diagnosis was made. This indicates that the condition is frequently unrecognized. Nine patients had had previous abdominal operations without relief of symptoms.

The condition is more commonly unilateral, but may involve both kidneys, a fact which must be remembered when considering operation.

Diagnosis: In the diagnosis of this lesion, the case history is important. A person in the second or third decade of life may complain of pain in the flank or abdomen. In most instances it is a periodic type of pain which may appear suddenly, become intense though seldom colicky, then gradually subside over a period of from one to several days. At the height of the attack,

reflex nausea and vomiting may be severe and may lead frequently to an erroneous diagnosis of an intraperitoneal lesion. In the presence of infection the attack may be initiated by a chill and fever. In other cases the pain may be continuous, dull, aching and boring, which type is more likely to occur in the late stages. In many cases the pain is most severe on arising and gradually subsides after the patient becomes active. This fact corroborates the previous assumption that interference with ureteral peristalsis is a more important factor in production of the hydronephrosis than the dropping of the kidney in the upright posture. The cessation of pain on resuming muscular activity after a night's rest probably can be attributed to a squeezing effect on the dilated pelvis which gradually expresses the urine that has accumulated during the night.

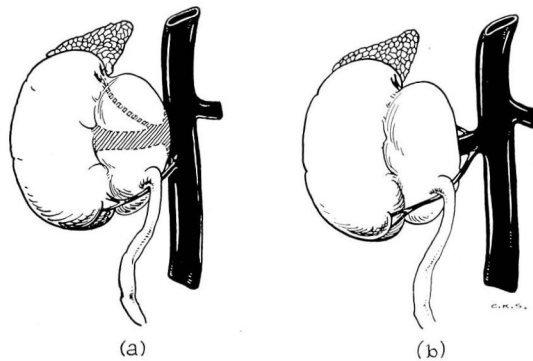


FIG. 1. Diagrammatic drawing showing manner in which the anomalous vessel produces ureteropelvic obstruction. (a) This vessel may be a branch of the aorta or (b) a branch of the renal artery.

Physical signs may not be striking. There is usually some tenderness in the costovertebral angle of the affected side which may be elicited only by first percussion. In rare instances, there may be a palpable mass in the kidney region. As many of these kidney pelves are uninfected, there may be negative urine which too often results in exoneration of the urinary tract. The urinalysis, therefore, is not a reliable indication in the diagnosis. It is significant that in 50 per cent of our cases the urine was entirely normal.

The **diagnosis** can be arrived at only by making a pyelogram either by intravenous urography or retrograde pyelography after ureteral catheterization. If the former method is employed one must remember that kidney function may be impaired resulting in a delayed appearance of the dye in the renal pelvis. If the condition is suspected delayed films made 2 or even 3 hours after injection of the dye may demonstrate a hydronephrosis. Kidney function may be destroyed so completely that no visualization will occur. The characteristic picture in the moderately advanced case is a kettle drum type of hydronephrosis in an extrarenal pelvis. The opaque medium is sharply confined to

the pelvis and there seldom is any dye in the upper ureter, thus indicating the obstruction to be at the ureteropelvic junction. In the retrograde pyelogram one usually sees a high insertion of the ureter and often the angulation is such as to prevent the ureteral catheter from entering the renal pelvis (fig. 2).

All patients with hydronephrosis associated with ureteropelvic obstruction should be hospitalized for retrograde pyelography. Because of the stasis in the kidney, acute infection may complicate the procedure in spite of most careful precautions. The patient may become severely ill and require immediate surgical intervention.

The **treatment** is by surgical methods which may be conservative in an attempt to save the kidney, or radical such as nephrectomy in those cases in which the process has resulted in complete destruction of the kidney. The operation, therefore, is dependent upon the extent of kidney damage, which in turn is related to the duration of the disease. In our cases, the average duration of symptoms where nephrectomy was required was 7.2 years, as opposed to 4.1 years when conservative measures were employed. Thus the importance of early diagnosis is apparent.

Determinations of the kidney function are required to ascertain the degree of damage. If the kidney shows absence of function and the pyelogram reveals the large type of hydronephrosis, nephrectomy is indicated. When the function is diminished in a young person whose symptoms are of relatively short duration, a more conservative operation should be selected to save the kidney.

Various types of conservative operations have been advocated, the chief controversy revolving about the advisability of ligating the obstructive artery. Those who oppose this procedure call attention to the fact that the arteries to the kidney are so-called "end" arteries and that a division results in necrosis of the portion of the kidney supplied by that vessel. To save the artery, various plastic procedures have been devised involving two principles: (1) to draw the ureter away from the artery and (2) to divide the ureter and reimplant it into the kidney pelvis on the opposite side of the obstructing vessel. Good results have been reported by both methods.

Our experience, however, is that no ill effects follow ligation of the artery. The operation consists of exposing the ureter and renal pelvis through the usual incision, and demonstrating the obstructing artery. The latter is isolated and the portion lying over the ureter excised. Subsequently it is extremely important to completely free the ureter of all fibrous periureteral bands. Following this procedure the ureter usually affords good dependent drainage of the renal pelvis. It is advisable to pass a 12 or 14 F catheter from the pelvis into the ureter to exclude the possibility of concomitant ureteropelvic stricture.

The foregoing procedure was used in 21 of the 52 cases studied and the results have been uniformly good. Pain has been relieved in every case and, in most instances, there has been prompt improvement in kidney function and reduction in size of the hydronephrosis. The reduction may be a slow process and, in many cases, the pelvis never returns to an absolutely normal size; however this is unimportant if pain has been relieved and if the kidney functions

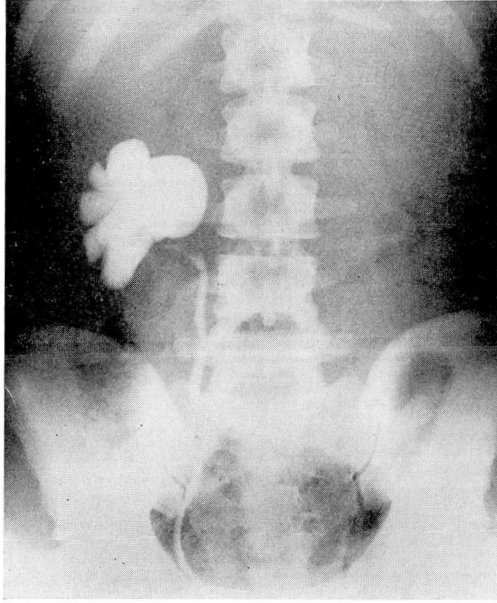


FIG. 2. Retrograde pyelogram showing hydronephrosis and angulation of ureter associated with ureteropelvic obstruction due to an aberrant artery.

satisfactorily. Such a kidney is capable of sustaining life in the event that the opposite kidney becomes impaired.

Summary

This experience indicates that ligation of an obstructing aberrant artery to the lower pole of the kidney is a safe and logical procedure in relieving this type of ureteropelvic obstruction. If there is subsequent destruction of kidney tissue, it is reflected neither in the convalescence nor end results obtained by the patient. It presents more promise in the average case than the more complicated plastic procedures which have been advocated because it avoids the opening and extensive handling of the renal pelvis, and does not interfere with the normal neuromuscular mechanism. Moreover, it minimizes the possibility of postoperative kidney infection which is the most frequent cause of failure in conservative surgery of the kidney.