

COMPLICATIONS OF HIATUS HERNIA

DONALD B. EFFLER, M. D.

Department of Thoracic Surgery

THE recognition of esophageal hiatus hernia as a pathologic entity is more widespread than might be anticipated. The impetus to diagnosis and clinical evaluation may be attributed primarily to the efforts of the roentgenologists. Careful study of the terminal esophagus and cardiac portion of the stomach is an integral part of every complete gastrointestinal study. For these reasons the incidence of hiatus hernia appears to be on the increase each year. Actually it is the incidence of recognition that is on the increase rather than the entity proper.

Hiatus hernia may be an incapacitating condition but is rarely a fatal one. The most troublesome complications of hiatus hernia are from bleeding, occult or massive. Peptic ulcers may occur and produce the disabling symptoms seen in ulcers elsewhere. Apparently perforation of an ulcer in a

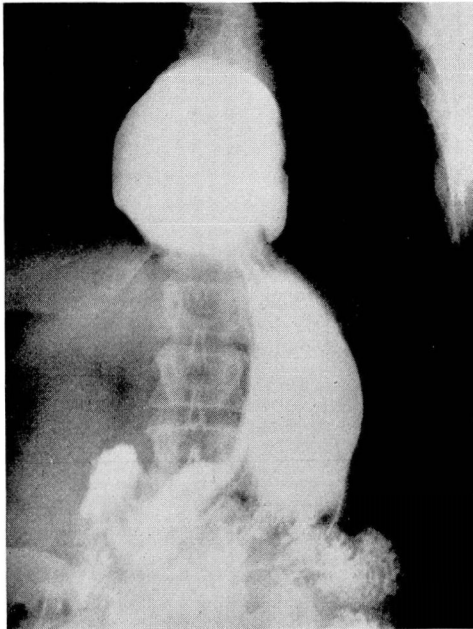


Fig. 1. Large para-esophageal hiatus hernia in 60 year old white man treated on numerous occasions for severe secondary anemia now believed due to occult bleeding from herniated stomach. Anemia totally corrected following transthoracic repair of hiatus hernia.

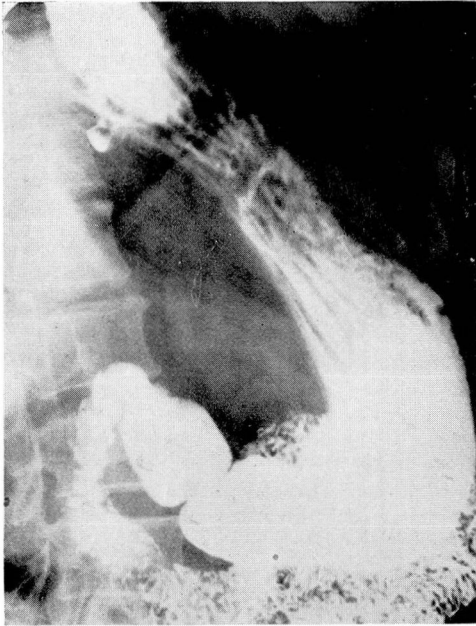


Fig. 2. Para-esophageal hiatus hernia in 63 year old white woman presenting typical peptic ulcer symptoms. Well-defined gastric ulcer apparent in the hiatus hernia. Complete relief of all symptoms followed transthoracic repair.

hiatus hernia is a rare entity as is strangulation of the incarcerated portion of the stomach.

In patients with esophageal hiatus hernia the stomach usually protrudes from the celomic cavity into the posterior mediastinum. This extension of the retroperitoneal portion of the stomach through the hiatus classifies this entity as a sliding hernia. A sac is also present since the reflection of the peritoneum on the anterior wall of the stomach is drawn through the hiatus by the herniated viscus. The recognition of this type of herniation is important in its surgical repair. Whereas inguinal sliding hernias descend externally into the scrotum, the hiatus hernia enters the posterior mediastinum and there causes compression or displacement of adjacent viscera. When one considers that the space normally occupied by the terminal third of the esophagus may be forced to accommodate one-half the volume of the stomach and its contents, it becomes apparent that anatomic compensation must occur. Usually the increased bulk of the hernia is taken up by the left pleural space; the resultant compression of the left lung is probably of no significance. Occasionally, however, there will be noticeable deviation of the cardiac silhouette to the right and pronounced displacement of the thoracic aorta to the left. It is in this latter case that the patient may complain of anginal type pain, exertional dyspnea and intermittent back or

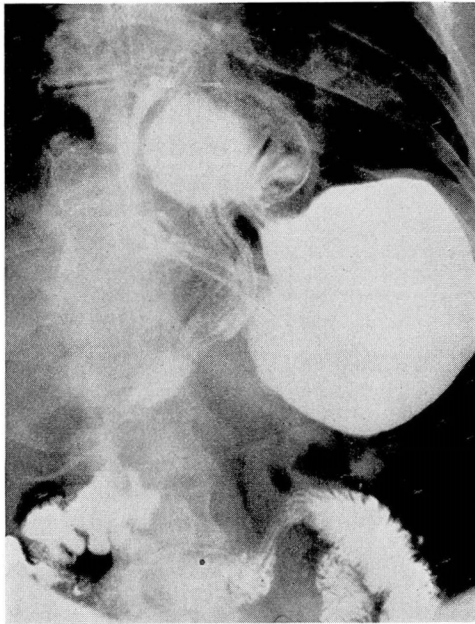


Fig. 3. Unusual manifestation of hiatus hernia. There is volvulus of stomach, and antrum of stomach appears herniated through the esophageal hiatus. Patient complained primarily of postprandial distress, fullness and frequent vomiting after meals.

shoulder pain. It is not the herniated viscus producing the symptoms in such a case but rather the displaced adjacent structures.

Any hernia that is unreduced is subject to complication; the hiatus hernia is no exception. Whereas the various inguinal herniations contain an assortment of viscera, the hiatus hernia consists almost exclusively of stomach and omental fat. For this reason the symptoms and resultant complications are usually associated with disturbed gastric physiology. The expected complications of hiatus hernia may be classified into three groups: 1. Hemorrhage, 2. Ulcer, 3. Volvulus. Each of these groups may be subdivided by the various manifestations and each may be an integral part of the other.

1. Hemorrhage
 - a. Occult
 - b. Massive (Hematemesis
(Melena)
2. Ulcer
 - a. Peptic
 - b. Traumatic
3. Volvulus

Hemorrhage: By far the most important complication of hiatus hernia is bleeding (fig. 1). This may be manifested only by a hypochromic anemia

without symptoms to localize the source. According to Brick,¹ the incidence of hiatus hernia among 3448 patients undergoing upper gastrointestinal roentgen examination was 8.93 per cent. This significant figure must be kept in mind when investigating any case of anemia which may be attributed to occult bleeding from the gastrointestinal tract.

The exact mechanism of bleeding in hiatus hernia is not understood. Undoubtedly many will bleed from ulceration of the gastric mucosa; on the other hand, all peptic ulcers in hiatus hernia do not manifest a bleeding tendency. Harrington² has suggested that bleeding is more frequently associated with incarceration of the hernia and erosion of the included gastric mucosa. The fact remains, however, that bleeding may vary quantitatively from occult to massive hemorrhage.

Ulcer: Many of the symptoms attributed to hiatus hernia parallel those of peptic ulcer.^{3,4} Nevertheless, few of these cases can be proven to have a demonstrable ulcer within the incarcerated hernia (fig. 2). This is surprising when one postulates the physiologic disturbance produced by an incarcerated portion of stomach whose filling and emptying processes are obviously abnormal. However, it must be kept in mind that failure of roentgenographic demonstration does not mean that an ulcer has not been or is not

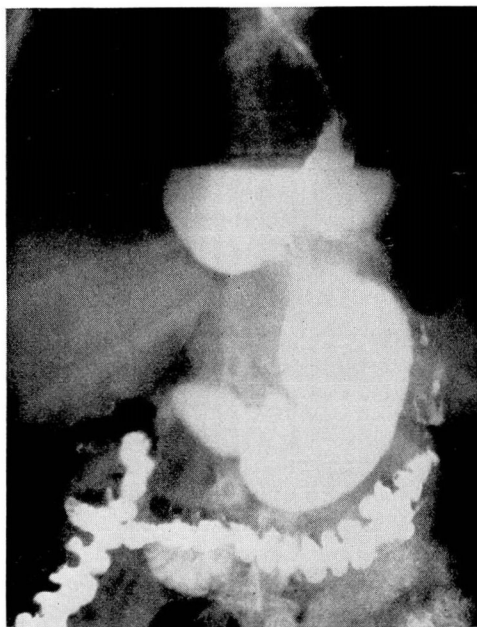


Fig. 4. Large esophageal hiatus hernia. Esophagus displaced anteriorly, still well-outlined by the contrast medium. Herniated portion of stomach partially incarcerated and incompletely obstructed. Patient complained of regurgitation following each meal and nocturnal retrosternal pain. Symptoms completely removed by transthoracic repair of hernia.

present. It must also be remembered that most patients with persistent severe symptoms of hiatus hernia have developed an "ulcer regime" of their own through dietary trial and error. It is reasonable to assume that many ulcers and mucosal erosions in hiatus hernia are transient in character since the size and contours of the sac may be in a constant state of flux.

The so-called "traumatic" or "callous" ulcers are described in many texts.⁵ These ulcers are said to be produced by the trauma of the adjacent, compressing structures on the impinging gastric mucosa. Such lesions may differ from the true peptic ulcer if they are produced mechanically; however, this matter is subject to question. In all probability the ulcer found in a hiatus hernia is no different than any other peptic ulcer.

Volvulus: The stomach is an extremely flexible viscus with four major attachments. The cardia and the pylorus constitute the most inflexible points of fixation, the ligaments of the greater and the lesser curvatures the more flexible (fig. 3). As the hollow viscus is forced into the mediastinum, a definite distortion of its normal contours takes place. The stomach may undergo torsion or fold back on itself so that the pylorus may be drawn above the cardia. Radiographic studies may demonstrate a bizarre configuration of the stomach with numerous fluid levels. In such cases, it becomes apparent that the organ is no longer capable of normal physiology. In this state the stomach is chronically obstructed to some degree.

Volvulus of the stomach may produce distressing clinical symptoms that are associated with obstruction and incarceration² (fig. 4). These patients vomit frequently soon after meals. Often regurgitation and eructation are forced by the patient for relief of severe retrosternal distress. Symptoms in these cases are usually worse after eating and when reclining. Often there will be severe pain behind the sternum that may simulate angina. When the viscus becomes distended by gas and fluid, there may be severe dyspnea and anxiety on the part of the patient who describes his discomfort as "pressure on my heart." These patients frequently impose voluntary social exile upon themselves because of the constant urge to regurgitate and eructate. In addition, they consume large quantities of various remedies with questionable value.

Comment

Other diseases are listed in the literature as complications of hiatus hernia. Authors have called attention to the association of gastric carcinoma, esophageal ulcer, diverticulum, esophagitis, hypertrophic gastritis, varices, etc. ^{1,3} with hiatus hernia. Actually these are separate entities and there is little evidence that they are conditions caused by the hernia.

Hiatus hernia may produce serious complications. Too frequently the impression has been given in the literature that this is a benign lesion capable only of mild dyspepsia and eructation. There is increasing clinical evidence which shows that some hiatus hernias are incapacitating by these

ulcer symptoms alone. The most serious complication, however, is the massive hemorrhage which may occur. Hiatus hernia must always be suspected when there is unexplained bleeding from the gastrointestinal system.

References

1. Brick, I. B.: Incidence of hiatus hernia and associated lesions diagnosed by roentgen ray. *Arch. Surg.* 58:419 (April) 1949.
2. Harrington, S. W.: Diagnosis and treatment of various types of diaphragmatic hernia. *Am. J. Surg.* 50:381 (Nov.) 1940.
3. Jankelson, I. R., and Morein, S.: Complications of diaphragmatic hernia. *Rev. Gastroenterol.* 7:134 (March-April) 1940.
4. Johnstone, A. S.: Peptic ulceration of esophagus with partial thoracic stomach. *Brit. J. Radiol.* 16:357 (Dec.) 1943.
5. Callander, C. L.: *Surgical Anatomy*. Philadelphia, W. B. Saunders Company, ed. 2, 1939, p. 239.