

# FATAL MAGNESIUM POISONING

## *Following Magnesium Sulfate, Glycerin, and Water Enema in Primary Megacolon\**

E. N. COLLINS, M.D., and P. W. RUSSELL, M.D.

Department of Gastroenterology

THE inclusion of magnesium sulfate in an enema in the presence of megacolon is extremely dangerous. Magnesium sulfate is unique in that it has both cathartic and anticonvulsant properties. When used to prevent convulsions it is given parenterally. When used as a cathartic, orally, in the presence of intestinal disease, the permeability of the intestinal membrane to magnesium may be increased and the effects on nerve function may predominate. The fact that the use of Epsom salt as a cathartic and in the treatment of biliary tract disease is usually harmless may lead to overlooking the possibility of its poisonous effects due to untoward absorption.

In the case reported death was due to magnesium poisoning resulting from absorption from an enema consisting of magnesium sulfate, glycerin, and water. An autopsy was performed.

### Case Report

A boy, aged 4, was admitted to the Cleveland Clinic Hospital on July 2, 1948 with a history of abdominal enlargement and constipation present since birth. The patient never had had a spontaneous bowel movement. He had taken mineral oil orally each day since birth, but had no bowel function unless he was given pint enemas of mineral oil or soapsuds 1 to 4 times daily in addition. A left retroperitoneal ganglionectomy had been performed in 1946, and anal dilatation in 1947, without alteration of bowel habit. He had vomited about once a month.

Physical examination revealed an undersized boy of 4 years, weighing 25 pounds, with symmetrical abdominal enlargement. The abdominal wall was slightly atrophic and of doughy consistency. There was a tympanitic note to percussion in all quadrants, and no organs or masses were palpable. Hypoperistalsis was evident on auscultation. Digital rectal examination revealed a relaxed sphincter and a dilated rectum. The remainder of the physical examination did not reveal abnormalities.

Examination of the blood disclosed 11.5 Gm. of hemoglobin per 100 cc., 5,870,000 erythrocytes, and 11,000 leukocytes. The fasting blood sugar was 66 mg. per 100 cc. The urinalysis, blood Wassermann and Kahn tests were negative. A barium enema revealed filling of the colon to the splenic flexure, with a striking dilatation of the rectum and sigmoid. Further filling of the colon was unnecessary, as an extensive accumulation of gas demonstrated dilatation of the colon in all segments (fig. 1).

The diagnosis of primary megacolon was made. To determine the possible effect of lumbar sympathectomy in compensating for the neuromuscular dysfunction of the colon, a lumbar subarachnoid injection of 75 mg. of procaine was performed on July 8. Despite

\*Dr. A. C. Corcoran, Research Division, assisted in the analysis of the factors involved in this case.

\*Dr. Edith Farnsworth, Northwestern University School of Medicine, kindly performed the analysis which is gratefully acknowledged.

adequate level of anesthesia, spontaneous evacuation of the bowel did not occur. On July 9, at 2 p.m., a caudal epidural injection of procaine was given, which produced relaxation of the anal sphincter and increased peristalsis in the small bowel, but did not result in the passage of feces. After complete recovery from the anesthetic, at 3:30 p.m. an enema was administered. Prostigmine was to have been given to cause evacuation. The enema consisted of 2 ounces of a solution of magnesium sulfate containing 30 Gm. of the hydrated salt, 4 ounces of glycerin, and 6 ounces of water. Without expelling the enema, the child "fell asleep" about 4 p.m. At 5 p.m. he was found to be comatose, with complete flaccid paralysis

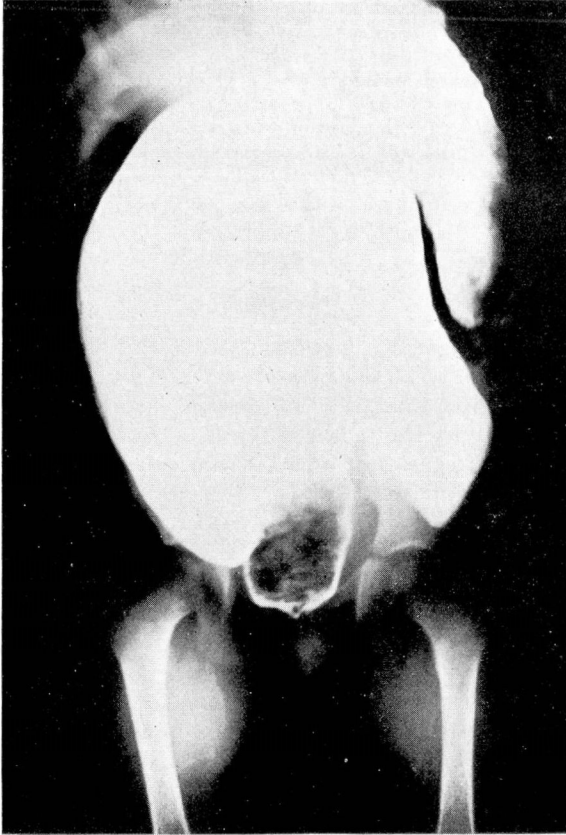


FIG. 1. Barium enema showing sigmoid and part of descending colon.

and absent pupillary reflexes. The respiratory rate was 8 per minute. This is important and characteristic. The pulse rate was 116 per minute. Cyanosis was absent. The patient was estimated to be in the second plane of third stage anesthesia. A rectal tube was immediately inserted. A subcutaneous injection of 0.4 cc. of prostigmine methylsulfate 1:4000 was given and caused release of about 1 pint of liquid fecal material. Following artificial respiration, oxygen, and 0.2 cc. of nikethamide subcutaneously the respiratory rate increased gradually to 16 per minute. The sequence of events indicated that the coma was related to the retained enema and probably to its magnesium content. Accordingly, at 6:30 p.m., 2 cc. of a 10 per cent solution of calcium gluconate was injected into the jugular vein, and an equal dose was

injected intramuscularly. Shortly thereafter, a slight increase in the respiratory rate was noted, but the neurological picture was unchanged. Despite continued supportive measures, including aspiration of additional fecal material, injections of 0.3 cc. of nikethamide, and 0.5 cc. of caffeine with sodium benzoate, the patient's condition remained the same until he died in respiratory paralysis at 10:30 p.m.

Postmortem examination showed the peritoneal cavity to be free of fluid and adhesions. The colon was hypertrophied, elongated, and grossly dilated, measuring 10 cm. in diameter. No perforations or stercoral ulcerations were found. There was a considerable quantity of fecal material in the left colon, but the small intestines were empty. A Meckel's diverticulum was encountered. There was no evidence of intestinal obstruction. Microscopic examination of the colon revealed thin mucosa infiltrated with leukocytes, an increased amount of submucosal connective tissue, and thickening of the muscular coats and serosa. Other significant microscopic findings included severe cerebral congestion with slight edema, congestion of the liver, lungs, and spleen, edema of the myocardium, and vacuolization of the adrenal cortex. A pathologic diagnosis of primary megacolon was made by Dr. John B. Hazard. Inasmuch as the gross and microscopic examination failed to reveal the cause of death, a specimen of heart blood was analyzed for magnesium.\*

The serum magnesium at autopsy was 30 mg. per 100 cc. (25 mEq per liter), and the serum calcium was 20.8 mg. per 100 cc.

### Discussion

It is known that progressive increase in the serum magnesium level above the normal of 2.4 mg. per 100 cc. results in nervous depression. In the cat these changes are apparently due to blocked neuromuscular transmission which affects different systems as the magnesium level rises;<sup>1,2</sup> tendon reflexes disappear at 6-14 mEq per liter, coma occurs at about 14.2 mEq per liter, natural respiration disappears at 15-20 mEq per liter, and corneal reflexes at 30-35 mEq per liter. All parts of the cardiac conduction system are also affected, S-A and A-V block occurring above a level of 15 mEq per liter. Cardiac arrest never precedes respiratory arrest, and usually occurs at levels of 27-44 mEq per liter. It may be concluded, therefore, that death in this case was due to respiratory paralysis.

Of 10 cases included in separate reports by Fraser<sup>3</sup> in 1909 and Boos<sup>4</sup> in 1910, only 2 presented the symptoms of coma and flaccid paralysis which constitute the known effects of magnesium poisoning; others manifested shock, syncope, or "intestinal intoxication" due to the local effects of overdosage. Maxwell<sup>5</sup> in 1929 reported the rapid onset of coma, paralysis, and death due to peritoneal absorption of an enema containing 15 Gm. of magnesium sulfate. This had been given to a patient whose sigmoid colon had been inadvertently transected. Byron<sup>6</sup> in 1939 reported 5 cases of fatal poisoning following oral administration of Epsom salt to children with helminthiasis. An unpublished fatality following rapid intravenous injection of 7.5 Gm. of magnesium sulfate is cited by Winkler, et al.<sup>7</sup> in 1942. In none of these 9 typical cases of magnesium poisoning, all of which were fatal, were there confirmatory laboratory data.

Fawcett and Gens<sup>8</sup> in 1943 reported 2 cases of magnesium poisoning following enemas, one presumptive, and the other the *first proved case*. One patient, a 2 year old boy, had an imperforate anus which had been treated with colos-

tomy followed by an abdominoperineal plastic operation. Two months post-operatively, an enema containing magnesium immediately resulted in flaccid paralysis, coma, and absent pupillary reflexes. Respiratory failure occurred a few hours later, and autopsy failed to reveal the cause of death. A 23 year old woman with ureteral calculus was given prostigmine and an enema containing 28 Gm. of magnesium sulfate. One hour later, she was found to be in a coma, with flaccid paralysis and sluggish pupils. One gram of calcium gluconate intravenously gave prompt improvement. Three hours later, the serum magnesium was 20.8 mg. per 100 cc., and the serum calcium 9.9 mg. per 100 cc. An additional 1 Gm. of calcium gluconate intravenously resulted in complete recovery of consciousness, at which time the serum magnesium was 15.4 mg. per 100 cc., and the serum calcium 11.2 mg. per 100 cc. Of the 11 reported typical cases of magnesium poisoning, this was the only one to recover.

A fact not sufficiently appreciated is that the gastrointestinal membrane is by no means impermeable to the salts of magnesium. Hirschfelder<sup>9</sup> found that 40 per cent of an oral dose of magnesium sulfate was absorbed within twenty-four hours; he emphasized that the rapid urinary excretion of magnesium which normally prevails prevented a significant rise in serum concentration, and that when excretion was depressed, as in nephritis, dangerous serum magnesium levels could be obtained with an ordinary oral dose. Van Liere<sup>10</sup> demonstrated in dogs 14 per cent absorption of magnesium in ninety minutes from ileal loops filled with 3.25 per cent anhydrous magnesium sulfate.

Winkler, et al. calculated the fraction of the body water in which magnesium is distributed following a known retention of an injection of magnesium sulfate. Assuming from their data that the increased magnesium concentration prevailed in 30 per cent of the body weight of our patient, it appears that this child absorbed at least 34 per cent of the 3000 mg. of magnesium present in the enema. The reason for this absorption was not evident from the postmortem examination. Other cases of primary megacolon are known to have received such enemas without untoward results; Bonar<sup>11</sup> repeatedly administered enemas containing 56 Gm. of magnesium sulfate to a 4 year old child with megacolon and obtained excellent evacuations of the bowel.

The only effective antidote in magnesium poisoning is parenteral administration of calcium ion. The proper dosage of calcium needed to antagonize a given magnesium excess has not been calculated. The response to calcium obtained in experimental animals appears immediately so that the dosage can best be judged by clinical improvement. This was also apparent in the case presented by Fawcett and Gens, who injected 90 mg. of calcium ion. The dose of 36 mg. of calcium ion used in our case would seem sufficient by comparing body weights, yet no clinical improvement was noted.

Curiously, the final serum calcium level was 20.8 mg. per 100 cc. This hypercalcemia is difficult to explain. Assuming a plasma volume of 570 cc., the total increase in serum calcium was about 57 mg., of which 36 mg. were injected, leaving an excess of at least 21 mg. of calcium in the serum. This might be regarded as a protective response of the body to hypermagnesemia.

We have not found this effect to be mentioned in the literature. That this hypercalcemia might also have blocked neuromuscular transmission seems unlikely, as higher levels of serum calcium are needed for such a depression to occur. We are, therefore, led to assume that the lack of response to calcium in this case was due not to under-dosage but to delay in its administration.

### Summary.

1. Fatal magnesium poisoning resulted from the absorption from an enema in a patient with primary megacolon.
2. The clinical signs of flaccid paralysis, slow respiratory rate, coma, and absent pupillary reflexes developing rapidly after the administration of magnesium sulfate must be promptly recognized if calcium therapy is to be beneficial.
3. The use of magnesium sulfate enemas is contraindicated in children with primary megacolon.

### References

1. Hoff, H. E., Smith, P. K., and Winkler, A. W.: Effects of magnesium on nervous system in relation to its concentration in serum. *Am. J. Physiol.* **130**:292-297 (Aug.) 1940.
2. Smith, P. K., Winkler, A. W., and Hoff, H. E.: Electrocardiographic changes and concentration of magnesium in serum following intravenous injection of magnesium salts. *Am. J. Physiol.* **126**:720-730 (July) 1939.
3. Fraser, C.: Epsom salts as a poison: with a record of a case of unusual symptoms due to this drug. *Lancet* **1**:1174-1176, 1909.
4. Boos, W. F.: Magnesium poisoning. *J.A.M.A.* **55**:2037-2042 (Dec. 10) 1910.
5. Maxwell, W. W.: Traumatic perforation of uterus with severance of rectum; report of a case. *Am. J. Obst. and Gynec.* **17**:96-102 (Jan.) 1929.
6. Byron, F. E.: Fatal results following administration of magnesium sulfate. *J. Malaya Br., Brit. M. A.* **3**:100-101 (June) 1939.
7. Winkler, A. W., Smith, P. K., and Hoff, H. E.: Intravenous magnesium sulfate in treatments of nephritic convulsions in adults. *J. Clin. Investigation* **21**:207-216 (March) 1942.
8. Fawcett, D. W., and Gens, J. P.: Magnesium poisoning following enema of epsom salt solution. *J.A.M.A.* **123**:1028-1029 (Dec. 18) 1943.
9. Hirschfelder, A. D.: Clinical manifestations of high and low plasma magnesium; dangers of epsom salt purgation in nephritis. *J.A.M.A.* **102**:1138-1141 (April 7) 1934.
10. Van Lier, E. J., Northrup, D. W., Stickney, J. C., and Richards, R. E.: Effect of anemia anoxia on absorption of isotonic magnesium sulfate from small intestine. *Proc. Soc. Exper. Biol. and Med.* **64**:62-64 (Jan.) 1947.
11. Bonar, B. E.: Pelvirectal acholasia (Hirschsprung's disease); temporary medical management by rectal administration of magnesium sulfate. *Am. J. Dis. Child.* **48**:123-129 (July) 1934.