

# MESENTERIC CYST WITH INTESTINAL OBSTRUCTION

## *Report of a Case*

ARTHUR G. MICHELS, M.D., and THOMAS E. JONES, M.D.

Department of Surgery

THE mesenteric cyst is probably the least common of all abdominal tumors. The rarity of this lesion is indicated by Keesey<sup>1</sup> who reported only 2 cases in 200,000 admissions to a Duluth hospital. The incidence at the Cleveland Clinic during the past fourteen years has been identical: 3 proved cases from a total of 300,000 new patients examined. The first recorded case was found on autopsy in 1507 by Benevieni,<sup>2</sup> and subsequent reports have appeared at intervals, the first successful operation and cyst removal having been performed by Tillaux in 1880.<sup>3</sup>

Numerous theories have been advanced for the origin of such cysts, with many sources implicated, such as hydatid, Meckel's diverticulum, and mesenteric lymphatics. Some writers consider that all cysts are embryonic in origin and initiated by obstruction of existing lymphatic channels or by growth of congenitally misplaced lymphatic tissue which does not communicate with the vascular system. However, the absence of demonstrable inflammation in the mesentery of the usual case makes the theory of lymphatic trunk obstruction a less likely cause. The consensus favors the development of mesenteric cysts from misplaced bits of lymphatic tissue which proliferate and then accumulate fluid because of absence of communication with the remainder of the lymphatic system.

In the usual case the history of a gradually enlarging abdomen is obtained and the most frequent cause for hospital admission is intestinal obstruction. A case of mesenteric cyst complicated by such obstruction is presented.

## Case Report

A 7 year old girl was admitted to the hospital with a history of severe intermitten abdominal cramps and occasional vomiting for one week. Seven days before admission the patient had developed sharp recurrent periumbilical pain frequently accompanied by vomiting of gastric contents. The child lay doubled on hands and knees and cried intermittently with pain, rubbing her stomach while in distress. Between spasms she appeared moderately comfortable until the onset of another cramp which usually appeared every half hour to an hour. She had been hospitalized elsewhere for three days previous to admission and intravenous fluid had been prescribed while roentgen studies were made. The patient had had several formed stools the week previously, the most recent on the day before admission to the Cleveland Clinic.

Past history disclosed that approximately one year prior to admission the girl had experienced a somewhat similar attack of pain for which an appendectomy had been performed. At operation an "acute ileitis" was observed, involving a number of plaques and

enlarged mesenteric lymph glands. Since convalescence the patient had had several attacks of similar pain which had persisted two to three days, in each case attributed to dietary indiscretion.

Physical examination disclosed a well-developed, moderately well-nourished but fatigued girl who appeared acutely ill, frequently remained motionless, face down, with hands and knees doubled, and who cried intermittently with pain while massaging her abdomen. The pain lasted three to five minutes only to reappear. Her blood pressure was 110/70, temperature 99 F., pulse 120, and respiration 20. The tongue was moist and of good color; the skin was clear and dry, with lung fields normal to auscultation and percussion. The heart rhythm was regular, with no enlargement or murmurs. The child's abdomen was soft and non-tender when not experiencing abdominal pain. No distinct masses were evident and investigation for bowel sounds proved unsatisfactory during cramps. Further examination disclosed a well-healed right lower quadrant McBurney scar and absence of hernia or visible peristalsis. Rectal examination revealed a firm movable left lower quadrant mass which was believed to be inspissated barium. The remainder of the examination did not reveal any abnormalities.

Laboratory examination disclosed the hemoglobin to be 12 Gm. while the white cell count was 9800. Urinalysis showed a specific gravity of 1.026 and was negative for sugar and albumin, although the sediment contained occasional white cells. The protein totalled 7.3 gr. per 100 cc.

Review of films taken elsewhere and admission flat film of the abdomen demonstrated barium in the cecum, ascending, transverse, and descending colon. There was a faint concentration of barium in the duodenum and a greatly dilated second and third portions of the duodenum with obstruction demonstrated near the ligament of Treitz, the exact cause undetermined (figs. 1a and b).

The patient was placed on gastric suction with a small Miller-Abbott tube, and fluids were given by clysis and vein to restore the electrolyte balance. Chlorides rose from a low of 379 mg. per cent on the second hospital day to 511 mg. per cent on the third hospital day, while the carbon dioxide combining power rose from 38.5 mg. per 100 cc. on the second hospital day to 55.7 mg. per 100 cc. on the third hospital day. The colon was gradually emptied of barium by repeated oil retention and saline enemas. With decompression of the stomach and duodenum the abdominal cramps subsided in two days and the patient began to improve progressively. Temperature varied during the preoperative period between 98.6 F. and 99.8 F.

On the sixth hospital day she was taken to surgery and through a midline upper abdominal incision the abdominal cavity was explored. The small bowel immediately presented an unusual configuration and further exploration disclosed a dumbbell-shaped cyst approximately 8 by 10 cm. lying along the mesenteric border of the jejunum 5 inches distal to the ligament of Treitz. The heavy liquid-filled cyst had acted as a pendulum swinging the entire small bowel in a clockwise rotation with the base of the congenitally short mesentery acting as the pivot point. With rotation of a full turn the jejunum had become obstructed just distal to the ligament of Treitz. The obstruction was apparently not always complete and the degree depended upon the tightness with which the small bowel was twisted about the mesenteric pedicle. Concomitant with the findings was severe mesenteric adenitis of the small bowel but no evidence of regional ileitis as previously reported. By rotating the mass of small bowel counter clockwise a full turn the volvulus was reduced and the mesenteric cyst then dissected free from the mesentery without impairment of the adjacent small bowel blood supply. During the dissection the cyst was fractured and approximately 300 cc. of clear yellow fluid was removed by suction. Following cyst removal the rent in the mesentery of the jejunum was closed and the abdominal wall sutured in layers.

The postoperative course was uneventful and afebrile. The patient passed a formed stool on the fourth postoperative day and was discharged asymptomatic on the seventh postoperative day.

The pathologic diagnosis was a simple mesenteric cyst, which on microscopic examination, showed highly vascular fibrous tissue and smooth muscle covered by thin flattened well-separated cells.

### Discussion

The contents of mesenteric cysts denote the accidents that have befallen the cyst and which infrequently have any bearing on the etiology. The fluid within the cyst commonly is of two sorts: colorless lymphatic or serous fluid found in approximately 36 per cent, with the second major group containing chylous fluid which has the appearance and consistency of yellow-white milk (35 per cent). Occasionally other contents are present such as blood, sebaceous material, dermoid contents or malignant cells. The typical serous fluid reaction is alkaline, with a specific reaction of 1.015-1.7 and some cell debris; should

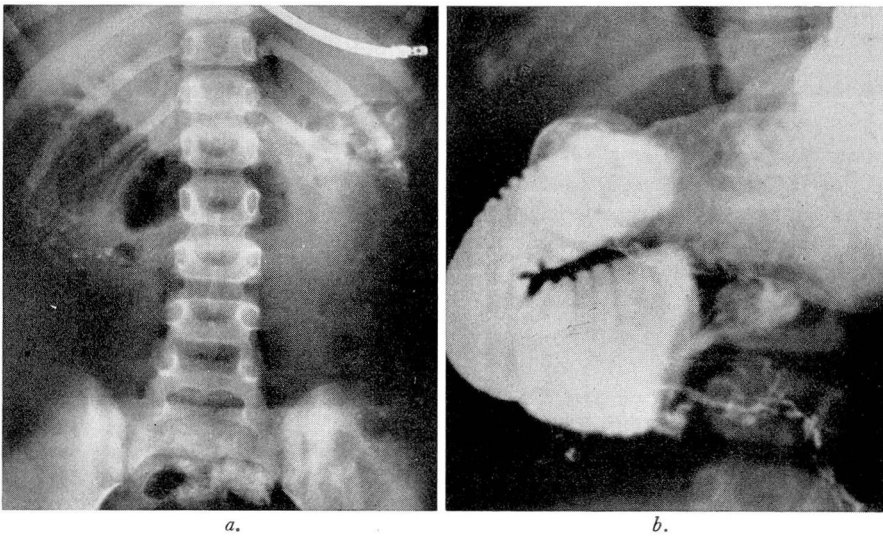


FIG. 1. (a) Abdominal film demonstrating gas in distended duodenum. Tube in stomach. (b) Barium outlining distended duodenum and stomach with point of obstruction in distal portion of duodenum.

lymphatics be draining from the intestinal tract to the cyst region the fluid may contain a high fat percentage. Chemical analysis of the cyst fluids discloses concentrations of sodium, chlorides, nitrogen, protein, fat and cholesterol which approximate their respective concentrations in plasma.

Mesenteric cysts may occur in any part of the mesentery of the small or large bowel but are most commonly found in the mesentery of the ileum (31 per cent). Ladd and Gross<sup>4</sup> found that in only 2 of their 8 cases the cyst involved the transverse mesocolon and mesosigmoid respectively. Of the 129 cases reviewed by Warfield<sup>5</sup> approximately 48 per cent were in the small bowel mesentery, 50 per cent in the large bowel mesentery and 2 per cent in the mesoappendix or gastrohepatic mesentery.

The cysts rarely produce dysfunction when quite small, and usually yield symptoms justifying operation only after reaching a large size, some large enough to fill the entire abdomen. The majority are unilocular, and a few

multicystic with ducts connecting two or more chambers. In Warfield's series<sup>5</sup> 50 per cent were unilocular while the other half were composed of two or more compartments. The cysts may be situated anywhere between the peritoneal leaves of the mesentery from the mesenteric base to the enteric border. The thin cyst wall consists chiefly of connective tissue with no demonstrable muscular coat, and is lined with simple columnar or flattened epithelium. The cyst may project from either or both surfaces of the mesentery to form a dumb-bell or saddle-shaped structure which, as it increases in size, may obstruct the enclosed loop of the intestine by pressure or kinking.

Many descriptions in the literature confuse true mesenteric (lymphatic) cysts with enteric cysts, which are actually duplications. Ladd and Gross<sup>4</sup> explain that these two lesions are pathologically different and require different forms of treatment. The duplication is a thick-walled structure which has a serous coat, two layers of smooth muscle, and a mucous membrane lining. The removal of this type of structure intimately associated with the intestine may involve considerable adjacent bowel trauma and injury to the blood supply of both the duplication and segment of the intestine, as they are nourished by the same vessels. In contrast, the thin mesenteric cyst wall has no muscular coat or mucosal lining and can be dissected free from the bowel and mesentery by following the lines of cleavage without injuring the bowel or its blood supply, as illustrated in the foregoing case report.

There are no pathognomonic signs of this disease. Symptoms of mesenteric cysts are rarely detected in infancy but are more usual the first decade of life. Intestinal obstruction occurs in approximately one third of the cases and is often produced by the progressive narrowing or kinking of the bowel from the mechanical action of the enlarging cyst. Complications such as hemorrhage into the cyst, rupture of the cyst into the peritoneal cavity, torsion of the cyst or impaction into the pelvis, have all been reported. Several observations suggest a diagnosis of mesenteric cyst; a palpable abdominal mass with great mobility in the transverse plane, fluid wave in the mass, or a soft tissue gasless mass on x-ray studies. If a mass is demonstrated by roentgenograms and lies in front of the intestine the diagnosis of omental cyst should be considered.

The treatment is entirely surgical with emphasis on the treatment of the complications. The technical procedures of cyst removal are not difficult and recurrences infrequent. The procedure of choice is enucleation or dissection of the cyst out from the mesentery peeling away the peritoneal leaves from the underlying mass and displacing the important blood vessels from the line of dissection. This procedure involves the lowest mortality (9 per cent). Other procedures have been used with less degree of success such as resection of the cyst and adjacent portion of the intestine with primary side-to-side anastomosis (mortality 27 per cent), and marsupialization of the cyst (mortality 16 per cent). Of the 129 cases reviewed by Warfield<sup>5</sup> the 18 per cent fatalities were equally divided by sex; 52 per cent in patients of 5 years or younger; 23 per cent from five to thirty years of age and 25 per cent of the patients incurring fatalities were over 30 years of age.

### Summary

A case of mesenteric cyst of the jejunum was characterized by intermittent obstructive symptoms for more than one year and followed by signs of complete intestinal obstruction. At operation a dumbbell-shaped cyst was disclosed which had produced a volvulus of the entire small bowel and obstruction just distal to the ligament of Treitz. Following removal of the cyst and reduction of the volvulus the patient attained an uneventful recovery and was discharged asymptomatic.

### References

1. Keesey, W. E.: Cysts of mesentery; review of literature and report of case. *Illinois M. J.* **73**:333-336 (April) 1938.
2. Benevieni, cited by Warfield, J. O., Jr.<sup>5</sup>
3. Tillaux, cited by Warfield, J. O., Jr.<sup>5</sup>
4. Ladd, W. E., and Gross, R. E.: *Abdominal Surgery of Infancy and Childhood* (Philadelphia: W. B. Saunders Company, 1941).
5. Warfield, J. O., Jr.: Study of mesenteric cysts with report of 2 recent cases. *Ann. Surg.* **96**:329-339 (Sept.) 1932.