

OCULAR HEMORRHAGES

ROSCOE J. KENNEDY, M.D.

Department of Ophthalmology

Ocular hemorrhages are important not only because they produce visual loss but also because they usually indicate a disorder elsewhere in the body. One can roughly classify them in five main groups: external, vitreous, preretinal, retinal, and choroidal.

Of the external hemorrhages the most common is the subconjunctival hemorrhage, which is usually of no importance and may result from trauma or occur spontaneously. However, it is of great concern to the average patient. In older people subconjunctival hemorrhage suggests vessel weakness and warrants further investigation. A complete examination should be made for evidence of arteriosclerosis of the fundus as well as elsewhere in the body. Large hemorrhages may be caused by blows or falls on the head; these hemorrhages may also result from basal skull fractures with accompanying extravasation of blood along the floor of the orbit. Severe compression of the chest, scurvy, or purpura may also produce extensive hemorrhages. However, this never interferes with sight, and treatment consists of conservative measures such as warm compresses, dionin 2 per cent, or merthiolate ointment (ophthalmic 1:5000). Absorption of the extravasation usually requires about two weeks.

Vitreous hemorrhages of significant size interfere with the vision but are usually painless. They may result from trauma, arteriosclerosis, or inflammation of the retina, or may occur without apparent cause. In massive hemorrhages the light reflex is absent.

There is a severe type of recurring hemorrhage into the vitreous which occurs in adolescence, usually in males, and is known as Eales' disease. The disease tends to last many years and is often thought to be of tuberculous origin, e.g. tuberculous peripblebitis. The bleeding is most often from the ciliary body or occasionally from the retina. One should suspect an endocrine disorder, especially of the thyroid and pituitary glands, in this type of hemorrhage. Hemorrhages into the vitreous from the retina are usually of the preretinal or subhyaloid type, that is, occurring between the retina and the vitreous. The bleeding is usually of venous origin and represents long-standing vascular disease. The shape of the clot is ordinarily that of a half circle with the straight portion above. Vitreous hemorrhages occur in the macular region and are usually of considerable size and, because of their location, interfere seriously with vision. They usually are absorbed but tend to recur and

may break through into the vitreous. This type may be due to trauma but is most frequently due to arteriosclerosis and is not uncommon in cases of subarachnoid hemorrhage. Rest is an important factor in treatment.

One of the serious sequelae of vitreous hemorrhage is retinitis proliferans, in which there is a connective tissue proliferation which may lead to retinal detachment. The unabsorbed blood is organized by the growth of fibroblasts into it and the formation of new blood vessels. In diabetes complicated by retinitis proliferans the blood vessels are formed first, followed by the connective tissue.

Occlusion of a Vessel

The two main vessels of special concern are the central retinal artery and vein, either of which may be occluded and cause hemorrhages in the eye. Occlusion of the artery is serious. There is a sudden loss of sight. Upon examination the arteries appear narrowed, with smaller ones obliterated, and usually all arteries appear darker than normal. The disk is pale, and the retina is milk-white. The macula is prominent, and the "cherry-red spot" is present due to a red reflex from the choroid. It may also occur in amaurotic family idiocy. There may or may not be hemorrhages, which, if present, are usually small and near the disk. Pressure on the eyeball will empty the veins if the occlusion is incomplete. This occlusion of the retinal artery may occur with mitral stenosis.

Occlusion of the central vein may be complete or involve only one of its branches, and onset with loss of vision is usually less abrupt than that of occlusion of the artery. Examination reveals a typical picture of swollen disk and enormously dilated, tortuous veins of a dark red color. The retina is literally covered with superficial and deep hemorrhages of all sizes and shapes which often occur also on the disk. The superficial hemorrhages are striate and flame shaped, whereas the deep hemorrhages are round and irregular. The arteries are narrow. Sight is impaired, usually unilaterally but sometimes bilaterally. If pressure is placed on the globe the veins will not collapse. In some cases only a branch may be involved, in which event there is little disturbance of vision. With macular involvement after absorption there is likely to be a "hole" in the macula having a red, punched-out appearance and due to degeneration following edema. Many of these cases are complicated by secondary glaucoma, offering a serious prognosis. Today many of these eyes are saved by the use of heparin, dicumarol, and deep diathermy.

Hemorrhages in the Uveal Tract

Hemorrhages in the uveal tract may be due to (1) overdistention of vessels, e.g. in iris, (2) fragility of vessels, e.g. arteriosclerosis, or (3) in-

volvement of the blood itself, producing changes in the blood vessel walls, e.g. anemia, leukemia, purpura. Such hemorrhages may be traumatic or spontaneous and may occur in the iris and produce hyphemia. They usually are absorbed but may persist and produce blood-staining of the cornea.

Choroidal hemorrhages are important clinically because, if of significant size, they may produce permanent visual defects due to destruction of the overlying retina. Choroidal hemorrhages are dark red in color, rounded, and invariably occur beneath the retinal vessels. These hemorrhages deprive the overlying retinal tissue of nourishment by pressure. Retinal hemorrhages are usually striated or flame shaped, and the superficial vessels rarely cross over them. Choroidal hemorrhages may be differentiated from tumor by their sudden onset and the fact that under transillumination they are usually more translucent than tumors. Absorption may take several months. They usually leave a scar which is smaller than the original hemorrhage, as shown by the following case, but if the macula is involved the damage to sight may be a great handicap.

Case Report

A man, aged 34, was first seen on November 12, 1946, complaining of a "blind spot" in the left eye. Examination at this time revealed a peripapillary hemorrhage on the temporal side. Visual acuity at this time was O.D. 6/6, O.S. 6/6.

On November 27, 1946 the patient returned with marked reduction in visual acuity of the left eye, the vision being reduced to 6/12. Fundus examination revealed an extensive choroidal hemorrhage starting just temporal to the disk and extending over to involve the macula. Visual field studies revealed a centrocecal scotoma (fig. 1). The patient was

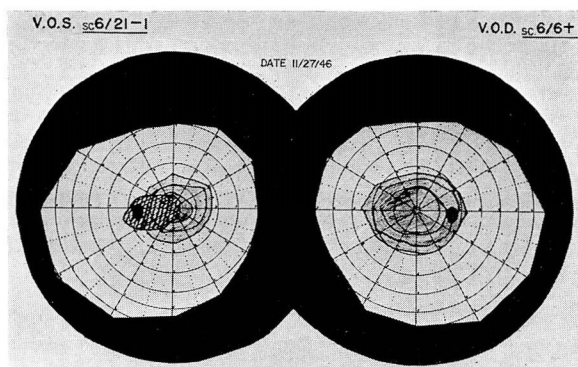


FIG. 1. O. S. Absolute centrocecal scotoma
Test objects: form 1/280
color 3/280
C.P. 10 ft.
Cooperation good
Features normal

given a course of intravenous typhoid therapy and deep diathermy to the eye. Progressive improvement was noted and a subsequent visual field study on March 31, 1947, showed only a paracentral scotoma and visual acuity restored to 6/6-1 (fig. 2).

Choroidal hemorrhages may be associated with acute choroiditis, vascular sclerosis, myopia, papilledema (rare), and the blood dyscrasias. A choroidal hemorrhage may be massive, but this usually occurs after operation.

Retinal Hemorrhage

Retinal hemorrhages of pathologic significance arise from the capillaries and are usually due to a dysfunction of the capillaries themselves rather than to arterial hypertension.

Duke-Elder¹ lists seven classes of conditions associated with capillary hemorrhages: (1) trauma, (2) obstruction, as thrombosis, papilledema, subarachnoid hemorrhage, (3) inflammatory conditions in the retina, (4) toxic states, e.g. acute febrile conditions such as malaria, influenza, (5) vascular retinopathies, e.g. nephritis, diabetes, arteriosclerosis, hypertension, (6) senile arteriosclerosis, and (7) blood dyscrasias.

The appearance of retinal hemorrhages varies according to their site. They are usually central and if they involve the superficial layers are striate and flame shaped, whereas in the deeper layers they are round and irregular. In contrast to the dark choroidal hemorrhages they are of a bright red color. They may last for months but have been known to disappear in three to four days.

The vascular retinopathies are characterized by hemorrhage and exudate in addition to sclerosis, hypertension, and toxemia.

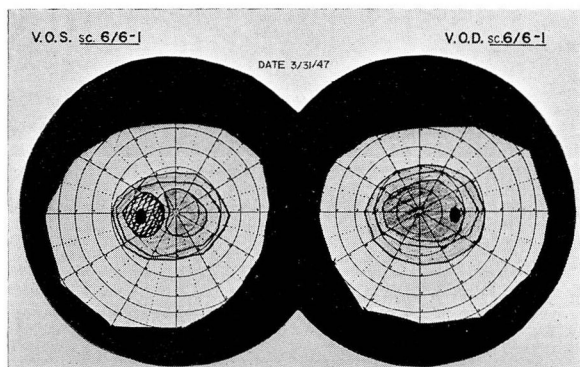


FIG. 2. Test objects: form 1/280
color 3/280
C.P. 10 ft.
Cooperation good
Features normal

The main changes in diabetic retinopathy are hemorrhages and exudates.² The condition is usually bilateral, and the hemorrhages are often punctate, tending to occur first in the periphery, especially between the temporal vessels and about the disk. They may be of any size, mostly round, small, and deep, and may be superficial and flame shaped, as the retinitis of nephritis. The hemorrhages are usually behind the retinal vessels, and there is usually little if any retinal edema. However, edema and exudates may be present, but they differ from those of renal retinopathy in being clear-cut patches rather than the cotton-wool type. A prominent feature associated with diabetes is early engorgement of the veins. There is no visual disturbance unless the macula is involved, and there is no constant relationship between the duration and severity of the diabetes. Hemorrhages may occur even when the condition is controlled. They are often situated away from the larger vessels and represent an escape of blood by diapedesis. Extensive hemorrhages may occur in the presence of arteriosclerosis.

Hypertension

Benign and essential hypertension are distinguished by the presence or absence of papilledema. Hemorrhages are usually superficial and flame shaped in the nerve fiber layer. There are many cotton-wool spots, and there may be deep hemorrhages and a star-shaped figure in the macula.

Blood Dyscrasias

In pernicious anemia the disk is pale and the fundus yellow. Retinal vessels show little change; veins may be engorged or tortuous. Hemorrhages are not numerous, have a regular distribution, tend to occur in the posterior pole, and are usually small and superficial. They seldom affect vision.

In leukemia the veins are dilated and tortuous, bright red, and often constricted at intervals. The arteries are small and pale. Hemorrhages are radial, small, linear, round, and irregular. They have a characteristic white center due to accumulated leukocytes, which may also occur in pernicious anemia.

In polycythemia vera, hemorrhages are rare. The fundus has a purplish color and the veins are dilated.

Treatment of hemorrhages due to blood dyscrasias depends upon the determination and subsequent correction of the causative factor.

References

1. Duke-Elder, W. S.: Textbook of Ophthalmology III. Diseases of the Inner Eye (St. Louis: C. V. Mosby Co., 1941) p. 2597.
2. Idem. p. 2706.