

are subject is an embolic accident due to dislodgment of a portion of a mural thrombus in the auricles. There is no evidence, however, that an accident of this kind is more likely to occur during anesthesia and operation than at other times.

Summary

Anesthesia and surgical operations do not increase the work load of the heart to an important degree. Patients who have organic heart disease but who have been able to carry on normal daily activities without symptoms referable to the heart can be expected to tolerate anesthesia and operation without difficulty, provided that anoxia and shock are avoided. On the other hand, if there have been symptoms of a diminished myocardial reserve or if congestive heart failure is present, a period of preoperative treatment with rest and digitalis is advisable. The treatment should be as thorough as possible during the interval for which the operation can be safely delayed. With adequate treatment, patients who have had congestive failure can be expected to tolerate anesthesia and surgery without difficulty. Postoperative complications, however, such as pulmonary embolism, atelectasis, pneumonia, and abdominal distention, are not well borne and may be responsible for a return of decompensation.

In patients who have auricular fibrillation with or without congestive failure, digitalis should be given before operation in sufficient amounts to reduce the ventricular rate to a satisfactory level. The drug usually should also be administered before operation to patients who have enlargement of the heart due to hypertension, even though there have been no symptoms of diminished myocardial reserve. There are a few heart conditions which are liable to result in sudden death, and the presence of these calls for special care in preventing anoxia, shock, and a reduction in blood pressure during anesthesia and operation. In patients who have one of these conditions, it is desirable to avoid the use of spinal anesthesia, if possible, because of the effect of this type of anesthesia on systemic blood pressure and coronary blood flow.

THE SYNDROME OF THE AURICULOTEMPORAL NERVE

LOUIS J. KARNOSH, M.D.
Department of Neuropsychiatry

Among the several atypical facial pains or pseudoneuralgias there occasionally occurs a peculiar disturbance of the auriculotemporal nerve when this structure becomes involved in parotid abscesses or

fistulae. Since parotid abscess is not an unusual complication of typhus fever and since this disease is endemic in eastern Europe, it is only natural that the first description of the condition was reported from Russia and Poland. Frey,¹ after whom the syndrome is frequently named, reported the first authentic case in 1923, although brief consideration was given to the same disorder by Lipsztat² in a Polish journal the year before. In 1931 Fridberg³ cited three examples of the disease in Russian women from Moscow, all in connection with parotitis complicating typhus.

This singular nerve lesion occurs in the wake of an abscess of the parotid gland, but the symptoms may not develop until several years after the original process has healed. Whenever the patient starts to eat, particularly if the food is hot, spicy, dry, or sour, the cheek over the parotid area turns red, and drops of perspiration appear on it. Occasionally the beads of perspiration are so prominent that they give the impression that a chronic parotid fistula is present and that the moisture is saliva. At the same time a feeling of fullness and flushing on the affected side of the face is experienced, while the mucous membrane of the corresponding buccal cavity feels unusually dry. These phenomena do not usually result from the mere movement of mastication unless there is actually food in the oral cavity. Stimulation of the posterior third of the tongue with a sour substance such as vinegar almost invariably brings on the perverted reactions characteristic of the syndrome.

While the symptoms often appear along with a facial nerve paralysis, they are in no direct way related to a disorder of this nerve. Therefore the appearance of so-called "crocodile tears", which is often encountered in a slowly regenerating Bell's palsy, is not correctly incorporated in the syndrome of the auriculotemporal nerve as has been erroneously suggested in some articles and textbooks. Neither does the irritation of the auriculotemporal nerve described in Costen's syndrome produce any of the features typical of the disease discussed in this paper.

Pain and other sensory disturbances are very common during mastication. The patient frequently complains of a deep boring ache in front of the tragus, which may be referred to the temple, the lower jaw, and the ipsilateral side of the tongue and throat. Blunting of tactile sensation may be found over the entire distribution of the auriculotemporal nerve, especially over the temple, the parotid area, and the entire ramus of the jaw.

Only a nerve which carries somatic sensory, vasodilator, and secretory fibers can be involved in the production of such a bizarre maldistribution of regenerated nerve function as presented in this syndrome. The auriculotemporal nerve is a large branch of the third division of the trigeminal trunk. It emerges to the facial skin area by winding

around the ramus of the jaw and contains different fibers conveying sensory impulses from the skin, vasodilator fibers destined for the subcutaneous blood vessels, and the secretory fibers for both sweat glands and the parotid. Secretory fibers for the sweat glands are derived from the cervical sympathetic system by way of the carotid and middle meningeal artery plexuses, while the parasympathetic salivatory fibers to the parotid join the auriculotemporal trunk by way of the otic ganglion from the ninth nerve. Hence as this nerve enters the substance of the parotid gland its components are of several varied physiologic functions.

It seems probable, as Ford⁴ explains, that in any disease of the parotid, particularly when its capsule is damaged, these functionally different categories of nerve fibers are badly disorganized. The result is a misdirection of some of the parasympathetic secretory fibers of the parotid gland. In the opinion of the writer these latter nerve elements escape through the ruptured gland capsule to seek connections with end organs in the skin, such as sweat glands and arterioles. Consequently, when the patient is eating, a volley of nervous impulses passes from the medulla over these parotid fibers, causing sweating and vasodilation instead of normal salivation.

While the parotid "bubo" of typhus is a complete stranger to the average American clinician, the parotitis following abdominal operations for suppurative disease is by no means rare and is quite capable of producing the complete auriculotemporal syndrome. Excision of an occasional mixed tumor of the same gland may result in a garbled regeneration of the auriculotemporal nerve and give rise to the same interesting symptomatology. Instances of both in a large Chicago clinic have been cited by the late Peter Bassoe.⁵

The writer has studied two patients, both of whom presented typical aspects of this syndrome following suppurative parotitis, and both complained of a typical facial pain. It is unique that each arrived with a bag of dry crackers and proceeded to demonstrate his symptoms by eating this particular food because it afforded the best display of his prandial discomforts.

Case 1. A man, aged 42, while travelling as a salesman five years before, had developed an infection in his right foot, which swelled suddenly in alarming fashion and necessitated his removal from a train and hospitalization. Suppurative subcutaneous tissue along the inner aspect of the right ankle and calf was incised several times. He eventually became delirious and was semicomatose for several weeks.

Metastatic parotid abscesses appeared on both sides, but the swelling on the right side was more pronounced and painful. Incision was made, and a salivatory fistula discharged for a period of four months.

Two years after recovery from what was apparently a near-fatal pyemia, the patient began to notice flushing and perspiration on the right cheek while eating.

Sour foods exaggerated the symptoms, as did dry material such as toast and crackers. During mastication he experienced some pain in the region of the right temporomandibular joint. Between meals the patient experienced no abnormal sensation other than an abnormally dry mouth.

Examination of the cranial nerves demonstrated a residual Bell's palsy on the right side. On activating the muscles of facial expression considerable clonic twitching of the zygomaticus and platysma was noted. There was some tenderness on pressure over the right tragus. Tactile sensation was diminished in front of the ear and inside the cheek.

Twenty minutes after the hypodermic injection of atropine sulphate the eating of several dry crackers produced no redness or perspiration over the affected area, clearly indicating that any depressant of parasympathetic function serves to remove the important objective symptoms.

Case 2. A woman, aged 38, presented herself with the history of right parotid abscess and fistula eighteen months previously following an operation for ovarian abscess. The parotid suppuration had developed while she was still in the hospital and was treated by ice applications, sedatives, and analgesics. Despite this the condition became complicated with a fistula and a complete facial paralysis.

Seven months prior to admission she sensed a hot, flushing feeling on the right half of the face, which perspired freely whenever she started eating. Five months later she began to experience paresthesia anterior to the right ear. The mucous membranes on the right side of the mouth felt dry. Because of all this and because of the coexisting facial paralysis the eating of any type of food was so distressing an ordeal that she took to eating only soup and milk-soaked bread as a regular diet. The Bell's palsy made her self-conscious to the point that she lived the life of a recluse.

Examination: The patient had a pronounced right facial paralysis with a positive Bell's eye phenomenon and an almost total immobilization of all facial muscles. On masticating three crackers the right buccal cavity filled with the food, the right cheek bulged, became flushed and very moist, and she drooled saliva from the right angle of the mouth.

Sensory findings are demonstrated in the figure. All other cranial components were normal, although there was some slight hyperesthesia on the right side of the throat and the posterior third of the tongue.

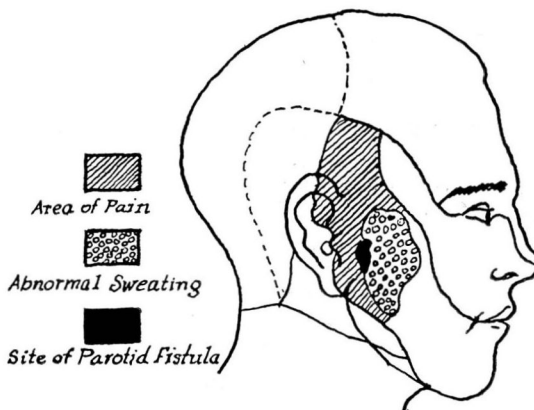


FIGURE. Demonstrating the abnormal secretory and sensory disturbances in the auriculotemporal syndrome following a suppurative parotitis.

Treatment of the syndrome of the auriculotemporal nerve is largely indicated by the assumption that the parasympathetic bulbar centers, by mediating their normal functions into the wrong end organs, are responsible for the perverted reflex behavior. Hence tincture of belladonna administered before meals has a positive relieving value, even though it retards salivation during the act of mastication.

A more radical procedure accidentally achieved good results when a surgeon injected the auriculotemporal nerve with alcohol while attempting to block the facial nerve which he assumed to be responsible for the disorder. Injection of the auriculotemporal nerve is a difficult maneuver. Probably the best technic is to block the entire third trigeminal branch or to inject a perineural effusion of 90 per cent alcohol. Such a relatively heroic measure is only justified if the embarrassments and discomforts associated with mastication of food are poorly tolerated.

REFERENCES

1. Frey, L.: Le syndrome du nerf auriculo-temporal. *Rev. neurol.* 2:97-104 (Aug.) 1923.
2. Lipsztat, N.: *Neurol. polska*, fasc. 6. 1922.
3. Fridberg, D.: Das auriculo-temporale Syndrom. *Deutsche Ztschr. f. Nervenhe.* 121:225-239. 1931.
4. Ford, F. R.: Paroxysmal lacrimation during eating as sequel of facial palsy (syndrome of crocodile tears); report of 4 cases with possible interpretation and comparison with auriculotemporal syndrome. *Arch. Neurol. & Psychiat.* 29:1279-1288 (June) 1933.
5. Bassoe, P.: Auriculotemporal syndrome and other vasomotor disturbances about head. *M. Clin. North America* 16:405-412 (Sept.) 1932.

MANAGEMENT OF THE PERMANENT COLOSTOMY

T. E. JONES, M.D., and R. W. KEHM, M.D.

Division of Surgery

The term, colostomy, or artificial anus, is of ominous significance to the patient. However, it is interesting to follow the change in his attitude from doubt and depression, through increasing confidence, and finally to personal pride in his ability to manage the artificial opening. As he begins to realize that he can actually lead a normal life despite this handicap, depression is replaced by planning for the future.

Many physicians who refer patients ultimately requiring colostomy to a surgeon see only a few such cases in the ordinary practice of medicine and as a result have little experience in its management. Since these same patients will return with many of their problems to the referring physician, we feel that our experience in dealing with such problems might well be described.