

psoriasis, especially when accompanied by arthritis, and erythema nodosum improve as a rule after protein shock treatments in conjunction with other therapeutic procedures. Shock treatment has been discontinued, except in rare instances, in otolaryngology and urology.

It is obvious from this brief review of the experience of fifteen years with intravenous typhoid shock therapy that a strong endorsement of this measure cannot be presented. Yet in properly selected cases it is helpful, and in Sydenham's chorea it definitely hastens recovery. Until specific therapy is available for many diseases of doubtful etiology or those in which ordinary treatment is unsatisfactory, we are justified in utilizing nonspecific measures.

REFERENCES

1. Howard, H. J.: Non-specific protein therapy in eye inflammations, with special reference to use of typhoid vaccine. *China M.J.* 41:395-407 (May) 1927.
2. Portmann, U. V., and Lough, R. R.: Roentgen therapy for acute encephalitis. *Am. J. Roentgenol.* 53:597-602 (June) 1945.

THE USE OF TANTALUM FOR REPAIR OF CRANIAL DEFECTS IN INFECTED CASES

W. JAMES GARDNER, M.D.

The primary purpose of this article is to demonstrate that presence of a tantalum implant does not impair healing of an infected wound. Secondly the author wishes to describe his experience with a hitherto untried method of dealing with abscess of the brain.

Tantalum, a newly available metal, has proved to be the most satisfactory material for repair of cranial defects.¹⁻¹⁰ Thus far it has been employed chiefly in secondary repair of cranial defects resulting from war wounds. A few surgeons have advocated its use in contaminated wounds, as in immediate repair of compound comminuted fractures of the skull.^{11,12,13,14} Infection, however, has been generally considered an absolute contraindication to the use of any metal implant.

Treatment of brain abscess by complete excision rather than drainage has yielded a lower morbidity in the author's experience, but the danger of cerebral fungus following radical excision has been a deterrent to the universal application of this method. Since cerebral fungus can be entirely prevented by closure of the skull defect with tantalum, the use of this material naturally suggested itself. Furthermore, tantalum has proved so inert by past experience¹⁵ that its use in infected cases seemed

entirely justifiable. In the past twenty months, therefore, tantalum has been used in 7 instances for closure of cranial defects resulting from excision of brain abscesses and in 1 case of acute osteomyelitis of the frontal bone. In this series there were six recoveries and two deaths. In 6 of the cases the wound healed by primary union, and in 2 infection occurred necessitating subsequent removal of the implant. The results indicate that if the responsible organism is sensitive to penicillin, and if the abscess is radically excised and the resulting cranial defect immediately closed with a tantalum implant, primary healing may be anticipated.

CASE REPORTS

Case 1*—A young man, aged 17 years, was hospitalized for three months after a frontal craniectomy for osteomyelitis of the skull complicating frontal sinusitis. During this time he had repeated operations for the drainage of brain abscesses of the left frontal and right occipital lobes. The organism was a penicillin-sensitive anaerobic *Streptococcus*. On June 27, 1944, the patient was extremely ill with meningitis and multiple brain abscesses in the right parieto-occipital region. On this date a flap of scalp was reflected and a bony opening 6.5 cm. in diameter was made over the site of the abscesses. The dura was excised, and the diseased brain was cut away with the electro-surgical loop to a depth of more than 5 cm. Several small subcortical abscesses were opened and removed. Palpation then disclosed a large firm subdural abscess adherent to the right side of the falx. This was incised, and about 2 ounces of thick pus escaped. The outer wall of this abscess was removed, and the medial wall was left attached to the falx. Ten cubic centimeters of penicillin solution, 1000 units per cubic centimeter, was introduced into the cavity in the brain tissue, after which a perforated tantalum implant was placed over the bony opening and fastened to the outer table of the skull with two tantalum screws. The dura was not closed. The scalp was then tightly closed with a buried tier of interrupted black silk stitches in the galca.† Drainage was not instituted. For the next forty-eight hours the patient received intramuscularly 10,000 units of penicillin every four hours; 10,000 units was injected beneath the scalp over the tantalum implant every four hours, and 10,000 units was given intrathecally every twelve hours. After forty-eight hours the intrathecal injections were discontinued and the injections beneath the scalp were reduced to twice a day. The latter injections and the intramuscular injections were continued until the sixteenth postoperative day. The temperature reached normal on the third day after operation and remained normal.

Convalescence was smooth, and the patient was discharged three weeks after operation. At no time was there any evidence of inflammation in the wound. When last seen fourteen months after operation he was free from symptoms and the cosmetic result was good.

Comment: This was the first case in which a tantalum implant was placed in an infected wound. The response to the operation was dra-

* This case was reported previously (ref. 13, case 15).

† The author has employed this method of closure of scalp wounds for many years. Careful placing of the subcutaneous sutures in the scalp renders skin sutures unnecessary and aids wound healing. Screws offer the best method of fastening the implant to the skull and, since properly sized tantalum screws are now available, all other methods should be considered obsolete. These methods of closure were employed in all reported cases.

matic especially in view of the long illness and the apparent hopelessness of the situation at the time of operation.

Case 2—A woman, aged 33, was admitted to the hospital January 20, 1945, with a complaint of headache. January 3 she had developed a right earache followed by discharge of pus, and the following day she had a high fever. Transient numbness of the left arm and leg occurred January 15, and on this date the family physician started treatment by intramuscular injections of penicillin.

On admission the patient was confused and complained of headache. There was early edema of the optic disks and a left homonymous hemianopsia. Spinal fluid pressure was 340 mm. of water; fluid was faintly cloudy and contained 1000 cells per c. mm., 65 per cent of which were polymorphonuclear leucocytes and 35 per cent lymphocytes. Spinal fluid culture was sterile. The clinical diagnosis was acute right temporal lobe abscess. Patient was given 15,000 units of penicillin intramuscularly every three hours, and sulfadiazine, 1 Gm. four times daily by mouth. Spinal fluid pressure on February 12 was 200 mm. of water, and the fluid contained 25 lymphocytes per c. mm. The patient became more drowsy, the left homonymous hemianopsia was still present, and there was a paresis of left angle of the mouth. The abscess was now considered to be in a favorable state for operation.

February 14, 1945, through a short linear incision above the right ear, an opening was made in the bone with a cranial burr. A brain cannula encountered an abscess at a depth of 2 or 3 cc. Eight cubic centimeters of thick creamy pus escaped from the cannula. The abscess cavity was irrigated with 10 cc. of a 1-1000 penicillin solution, the cannula removed, and the wound closed. Pus contained *Diplococcus pneumoniae* type I in pure culture. Because of the favorable character of the organism, radical excision of the abscess was decided upon.

The following day a small curved flap of scalp was reflected above the right ear, and the previous bony opening enlarged with a rongeur to a diameter of 7 cm. The dura

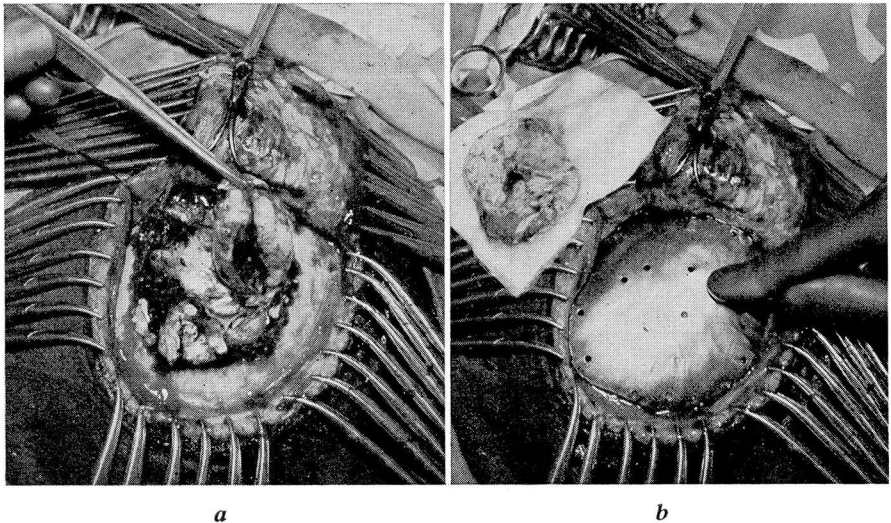


FIG. 1. Case 2. (a) The collapsed abscess has been dissected free except for its stalk. (b) The tantalum implant ready for fastening in place.

was incised, and the brain cortex overlying the wall of the abscess removed. A globular abscess approximately 6 cm. in diameter and attached by a short stalk to the dura on the upper surface of the petrous bone was freed from the surrounding brain and the dura by blunt dissection (fig. 1(a)).

The temporal horn of the ventricle was opened during the dissection and the abscess wall ruptured during its removal, spilling a large quantity of thick creamy pus. The resultant brain cavity was irrigated with saline solution. The dura was not closed. A perforated tantalum implant, 8 cm. in diameter, was fashioned and fastened over the skull defect (fig. 1(b)). Five grams of sulfanilamide crystals was placed on the outer surface of the implant. Scalp was closed in the usual fashion without drainage. Twenty-five thousand units of penicillin solution was then injected between the scalp and the implant. During the next forty-eight hours the patient received four intravenous injections of 50,000 units of specific pneumococcus type I antiserum and four injections of 20,000 units of penicillin beneath the scalp. In addition she received 15,000 units of penicillin intramuscularly every three hours, and 1 Gm. of sulfadiazine by mouth every four hours for sixteen days.

For two weeks 30 to 60 cc. of blood-tinged fluid was aspirated from beneath the scalp daily. On the first and second postoperative day cultures of this fluid disclosed *B. coli communis*, but subsequent cultures were sterile. Patient was discharged from the hospital March 3, free from symptoms except for left homonymous hemianopsia. When last examined eleven months after operation, she was in excellent health. There was still a left homonymous field defect.

Comment: This patient, in addition to penicillin and sulfonamides, received intravenously specific pneumococcus antiserum, which undoubtedly was a factor in her recovery.

Case 3—A boy, aged 6 years, was struck in the right eye with a snowball January 12, 1945. The following day he became drowsy, and two days later his temperature was 104 F. January 18 a right orbital abscess was drained, and January 19 he had a convulsion.

February 2 he was admitted to the hospital because of continued drowsiness and vomiting. Temperature, pulse, and respiration were normal. The right upper eyelid was swollen and indurated, and a small sinus persisted from drainage of the orbital abscess. There were no neurologic signs. X-rays of the skull disclosed clouding of the right antrum and ethmoid sinuses. The clinical diagnosis was right frontal lobe abscess secondary to sinusitis and orbital abscess. With the use of penicillin, 15,000 units given intramuscularly every three hours, he became alert and vomiting ceased.

February 13 he complained of headache in the right frontal region. February 19 bilateral papilledema was discovered, and a Babinski response appeared in the left foot. Operation was now deemed advisable.

February 19 a small flap of scalp was reflected from the right frontal region down to the supraorbital ridge. A bony opening 7 cm. in diameter was made with a rongeur. An exploring needle encountered a large abscess at a depth of 1 cm. beneath the cortex. Forty cubic centimeters of thick foul pus was aspirated from the abscess, after which the abscess wall was exposed by a cortical incision. The abscess was still too large to be removed through the bony opening. Incision was therefore made into the abscess cavity, and the contents removed with an aspirator. The incision in the wall of the abscess was closed with a hemostat, and by gentle traction and blunt dissection, the abscess wall was removed without further rupture (fig. 2). A stalk of fibrous tissue connected the abscess wall to the floor of the anterior fossa of the skull lateral to the olfactory groove. This was

freed readily by blunt dissection leaving a small area of roughened but otherwise intact dura. The cavity was irrigated with warm saline, and the dura was loosely closed. The bony opening was repaired with a perforated tantalum plate. Fifteen thousand units of penicillin was instilled into the brain cavity; 5 Gm. of sulfanilamide was placed on the outer surface of the implant, and the scalp was closed.

Pus culture revealed *Streptococcus salivarius*. For ten days the patient was given intramuscularly 15,000 units of penicillin every three hours, and oral sulfadiazine 1 Gm. four times daily. The first three days the scalp over the implant was tapped daily, a small amount of bloody fluid removed, and 15,000 units of penicillin instilled beneath the scalp. Thereafter no fluid collected, temperature was normal, convalescence was uneventful, and the patient was discharged from the hospital March 4 (fig. 3). Patient was readmitted to the hospital March 12 with a temperature of 102 F. and symptoms of meningitis. Spinal fluid pressure was over 700 mm. of water; fluid contained 800 polymorphonuclear cells; culture was sterile. Patient was treated with daily spinal puncture, intrathecal and intramuscular penicillin and sulfadiazine. He improved for a time but on March 24 became irrational. A needle, introduced through the scalp and through one of the tantalum plate perforations into the right frontal lobe, encountered a large abscess beneath the cortex. Seventy-five cubic centimeters of thick pus was aspirated; culture again revealed *Streptococcus salivarius*.

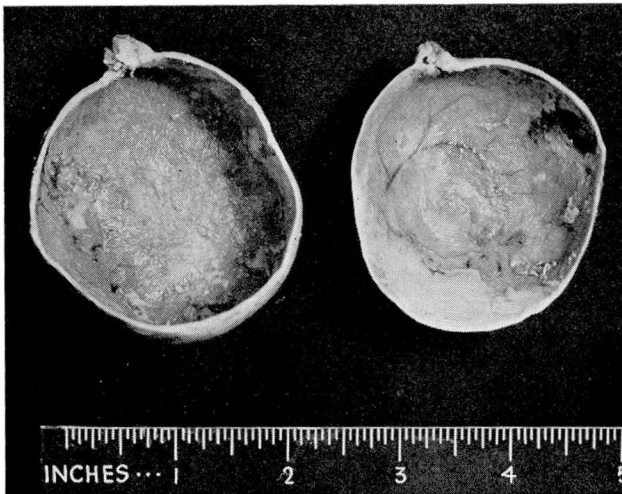

FIG. 2. Case 3. The abscess capsule after fixation.

March 29 the patient was reoperated upon. The tantalum implant appeared to be in perfect condition, enclosed in a smooth-walled membrane containing no fluid. The implant was removed, and a large irregularly shaped subcortical abscess was excised. The abscess wall was found attached to a circular area of dura on the floor of the anterior fossa lateral to the olfactory groove. The abscess wall was thin and contained many irregular ramifications, so that it was not possible to remove it entirely. The cavity was irrigated with saline, the tantalum plate reapplied, 50,000 units of penicillin injected into the cavity, and the scalp closed. A needle was inserted beneath the scalp at the

operative site for drainage and injection of penicillin. Patient did not rally and died thirty-six hours later.

Necropsy disclosed no pus in the ethmoid or sphenoid sinuses. There was marked edema of the contents of the right orbit with an area of erosion of the roof, 8 mm. in diameter. There was a small abscess of the head of the right caudate nucleus which had ruptured into the anterior horn of the right ventricle. It appeared that the brain abscess was secondary to infection within the orbit.

Comment: In retrospect it appears that recurrence of the abscess in this case could have been avoided by the more vigorous administration of penicillin. The total dosage was less than that given any other patient. This was due in part to the patient's terror of the needle.

The innocuous nature of tantalum is attested by the fact that the wall of the recurrent abscess reached to within a few millimeters of the

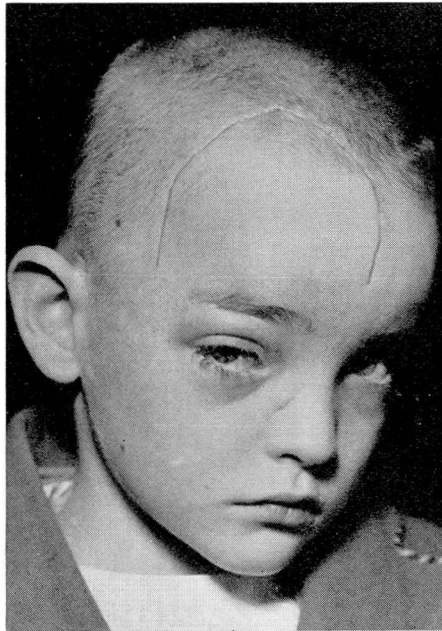

FIG. 3. Case 3. Wound healing on eleventh postoperative day.

inner surface of the implant and did not enclose it. It would certainly appear that the recurrence of the abscess was in no way due to the presence of the implant.

The lack of inclusion of the tantalum implant in the abscess cavity in spite of its proximity to the infectious process in this case suggested the possibility that tantalum might have an actual inhibiting effect upon

the growth of bacteria. In order to investigate the possibility, Dr. L. W. Diggs, director of the Department of Clinical Pathology, Cleveland Clinic, made the following studies.

1. Two blood plates were streaked with slant cultures of *B. coli* and one with *Staph. aureus*. Six to 8 sterile pieces of tantalum 3 mm. in diameter were dropped on the surface of each plate. The slants were incubated and observed at 24, 48 and 72 hours. The culture was satisfactory in all three plates. There was no evidence of inhibition of bacterial growth in the neighborhood of any of the pieces of tantalum.

2. Eight tubes containing brain-heart infusion broth were inoculated with 0.1 ml. of *Staph. aureus* suspension in saline. Two pieces of tantalum were placed in one tube, 4 in another, 8 and 20 in the third and fourth tubes, respectively. The other four tubes served as control. After 24 hours' incubation the broth was cloudy in all tubes, with no apparent inhibition of growth in the tubes containing 2, 4, 8 and 20 pieces.

3. Ten tubes of brain-heart infusion broth were inoculated with one drop of *B. coli* suspension. Two pieces of tantalum were placed in one tube, 9, 17 and 19 pieces in the second, third and fourth tubes, respectively. One of the tubes was placed in the icebox; the others were incubated. The growth rate as revealed by the turbidity changes in the ten tubes showed that the presence of pieces of tantalum had no effect on the rate of growth.

From these results it is concluded that the tantalum pieces had no apparent effect either as to inhibition or stimulation of the growth of *Staph. aureus* or *B. coli* on the mediae used and under the conditions outlined above.

Case 4—A young man, aged 17, was admitted to the hospital May 8, 1945, complaining of frontal headache. April 8 he developed headache and fever and was treated with penicillin. May 1 a swelling of his forehead appeared.

Patient was afebrile, mentally dull, and apathetic. There was doughy swelling above the frontal sinuses. X-ray of the skull showed clouding of both frontal sinuses and some mottling of the frontal bone just above the sinuses. Spinal fluid pressure was 580 mm. of water; fluid contained 35 cells, 95 per cent of which were lymphocytes. Clinical diagnosis was osteomyelitis of the frontal bone and brain abscess secondary to frontal sinusitis.

May 14, 1945, a curved flap of scalp was reflected from the frontal region down to the eyebrows, and a large periosteal abscess was evacuated. An eroded area of the skull just above the frontal sinus was exuding pus. Frontal bone was removed with a rongeur almost back to the coronal suture, together with upper portions of both frontal sinuses. Granulation tissue was present on the outer surface of the dura at the tip of the left frontal lobe. A cannula encountered thin foul-smelling pus at a depth of 2 cm. beneath the dura. A perforated implant was fashioned to cover the bony defect. An opening about 1 cm. in diameter was made in the implant over the site at which the abscess had been tapped. Five grams of sulfanilamide was placed on the outer surface of the implant, and the scalp was closed (fig. 4-5).

A stab wound was made over the opening in the implant and through it into the abscess cavity a cannula was inserted. A ureteral catheter was passed through the cannula for constant irrigation of the abscess cavity with dilute solution of penicillin. Culture of the pus disclosed *Alcaligenes faecalis* and *Streptococcus faecalis*. For four days the abscess cavity was irrigated continuously with a solution of 100 units penicillin per cc. saline, and then the cannula was removed.

On May 18 the wound was reopened because a clot had formed between the tantalum implant and the scalp. After evacuating the clot, the wound was closed with through and through sutures about a rubber tissue drain. Penicillin was introduced beneath the scalp daily for four days. It was then discontinued and the drain removed. May 22, 25, June 2 and 4, fluid aspirated daily from beneath the scalp contained *B. alcaligenes faecalis*. After the last date the fluid ceased to accumulate, and patient was discharged June 10. The patient received intramuscularly 15,000 units of penicillin.

USE OF TANTALUM

every three hours throughout his hospital stay together with 4 to 6 Gm. of sulfadiazine by mouth. When he was last heard from eight months after operation there were no symptoms, and the cosmetic result was excellent (fig. 6).

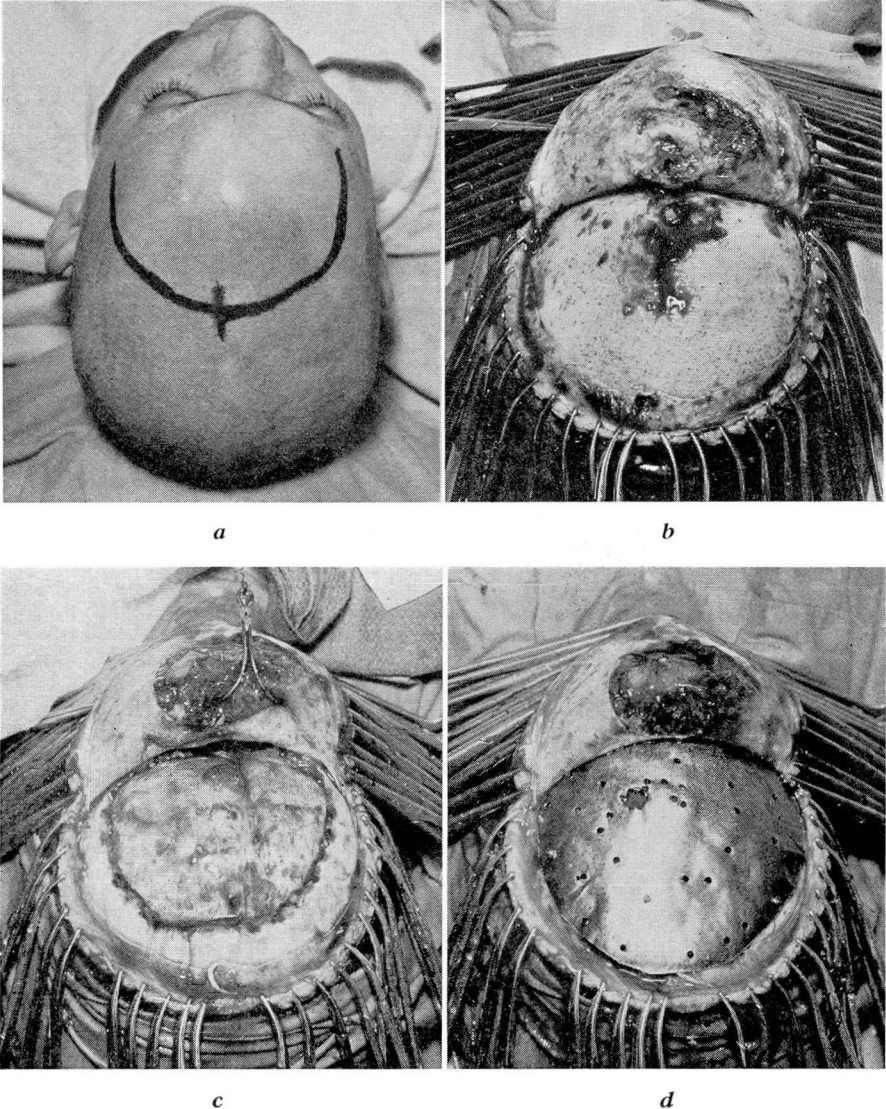


FIG. 4. Case 4. (a) Location of the incision. (b) Scalp has been reflected disclosing subperiosteal abscess. (c) Infected bone has been removed, including the upper portion of the frontal sinuses. Extradural granulation tissue is present over tip of left frontal lobe. (d) Tantalum implant in situ. The large perforation was made to permit insertion of cannula for drainage of brain abscess.

Comment: This is the most significant case in this series. Osteomyelitis of the frontal bone secondary to sinusitis carries a very high morbidity when treated by the usual method of removing the infected bone and leaving the scalp widely open. The result in this case was so gratifying that this method certainly deserves further trial. Even in case continuation of the infection should necessitate subsequent removal of the implant the patient will have lost nothing. The presence of the implant controls the abnormal pulsation of the uncovered brain and this splinting of the wound aids its healing.

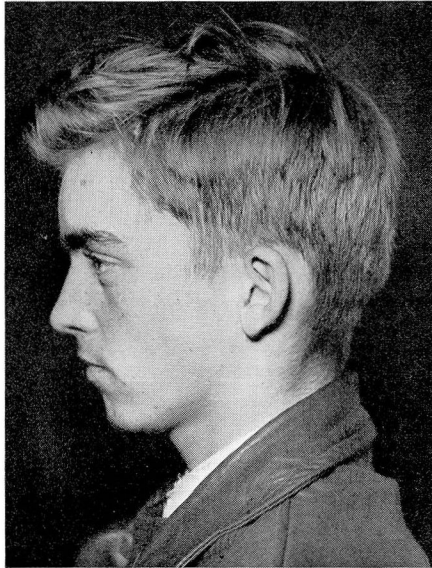

FIG. 5. Case 4. Cosmetic result five and one half months postoperative.

Case 5—A man, aged 49, had history of a draining left ear for forty years. April 11, 1945, he developed a chill and increased flow of pus from left ear. He was treated with penicillin and sulfadiazine. Stupor developed on May 6.

On admission to the hospital, May 8, patient was afebrile, semistuporous, aphasic, and there was pronounced choking of the optic disks. The left ear canal contained polyps and was discharging pus. The stupor lightened somewhat after a week's treatment with sulfonamides and penicillin, and a right homonymous hemianopsia was demonstrated. Diagnosis was abscess of the left temporal lobe.

May 15, a flap of scalp was reflected from the left temporal region, and a bony opening 8 cm. in diameter was made. Just above the mastoid an epidural abscess containing 6 to 8 cc. of thick pus was evacuated. Thickened dura at this point was adherent to the brain underneath. Dura was incised disclosing a fibrous stalk leading from the involved dura to a large abscess in the temporal lobe 1 cm. beneath the cortex. The abscess wall, which ruptured during removal, must have originally contained 3 to 4

ounces of pus. The abscess wall was excised in its entirety. The involved dura was likewise excised leaving a defect about 6 cm. in diameter. There was roughening of the superior surface of the outer portion of the petrous bone.

A perforated tantalum implant was fashioned and was fastened over the bony opening. The dura was not closed. The wound was flooded with penicillin solution, 1000 units per cc., and 5 Gm. of sulfanilamide was placed on the outer surface of the tantalum implant. The temporal muscle was repaired and the scalp closed. Two 18 gage needles were introduced through the scalp to the outer surface of the implant and through them the wound was irrigated continuously for the next five days with a saline solution of penicillin, 100 units per cc. Pus culture contained anaerobic *Streptococcus* and *Proteus vulgaris*. Patient was given orally sulfadiazine 4 to 6 Gm. daily, and intramuscularly penicillin, 20,000 units every three hours.

The patient's condition slowly improved but fluid aspirated from beneath the scalp at the operative site contained *Proteus vulgaris*. This fluid became purulent, and on May 31 the scalp wound was incised and drained and a left radical mastoidectomy performed. A collection of pus was found in the mastoid cavity, and through a bony dehiscence an extradural abscess was evacuated from the posterior fossa. The scalp wound and ear continued to drain. June 15 the scalp flap was reflected and the tantalum implant removed. A thick layer of granulation tissue was present on the outer surface of the newly formed dura. This granulation tissue was removed with a curet and the wound closed with through and through sutures about a rubber tissue drain. Patient was discharged from the hospital August 4. Because of lack of apposition of the wound surfaces, healing was slow. After continued use of pressure dressing, healing was finally complete on October 9. The patient returned to work on November 30. He was free from symptoms and the visual fields were normal. Drainage from the ear had ceased.

Comment: In this case, the mixed infection in the contiguous mastoid process and the chronic discharge from the ear canal, precluded the possibility of primary healing. The implant was introduced as a temporary expedient to prevent cerebral fungus and to encourage the local walling off of the infection.

Case 6—A boy, aged 15, had a discharging right ear for three years. He had been subject to headaches for two months and had been treated on two occasions in another hospital for meningitis with penicillin and sulfonamide. Three days prior to entry his consciousness became clouded. He was admitted to the hospital August 8, 1945, with temperature 101.5 F. He was stuporous with bilateral papilledema, right third nerve paralysis, and a discharging right ear. Spinal fluid pressure was over 700 mm. of water; fluid contained 800 leukocytes, 75 per cent of which were polymorphonuclear. Diagnosis was abscess of right temporal lobe.

An hour after entry, the right temporal region was trephined. The brain cannula encountered the abscess at a depth of 3 cm. Thirty cubic centimeters of foul pus was evacuated after which the cavity was irrigated with saline and 30,000 units of penicillin in 3 cc. of saline was then introduced into the abscess cavity. Cannula was removed and the wound closed. Culture of the pus disclosed *Bacillus coli* and *Staphylococcus albus*. Forty-eight hours later the patient experienced a sudden respiratory arrest. Retapping of the abscess released 2 ounces of thin pus, and respirations were re-established. It was decided to excise the abscess. A scalp flap was turned down in the right temporal region, and an opening in the temporal bone about 6 cm. in diameter was made with a rongeur. Dura was incised and an incision made through the brain cortex down to the abscess wall. The abscess wall was removed in its entirety by blunt dissection, although it was

ruptured during the process. A narrow but firm stalk anchored the abscess wall to the petrous ridge. The bone here, however, was not exposed. A perforated tantalum implant was placed over the bony defect. The dura was not closed. Five grams of sulfanilamide was placed in the brain cavity with 30,000 units of penicillin in 3 cc. of solution. The wound was closed. Fluid which continued to collect beneath the scalp over the implant was aspirated each day for ten days and penicillin was injected. The patient was also given intramuscularly 30,000 units of penicillin every three hours for twenty-five days and orally was given sulfadiazine. Fluid from beneath the scalp became progressively more turbid until it was decidedly purulent. Culture of this fluid showed consistently a pure growth of *B. coli*. August 24, through and through drainage of the scalp wound was established and the wound irrigated once every hour for several days with a 1-10,000 phenyl mercuric borate solution. Patient was out of bed and offered no complaint, but the scalp and the ear continued to drain.

September 11, a right mastoidectomy was performed and a cholesteatoma was removed from the mastoid antrum. September 19, the previous scalp incision was reopened and the tantalum plate removed. A thick layer of granulation tissue on the dense newly formed dura and on the under surface of the scalp was removed with curet. Wound was closed with through and through silk worm gut suture about a single rubber tissue drain. Convalescence was satisfactory and the patient was discharged from the hospital September 30, 1945. On October 27 the scalp wound and ear canal had ceased draining and the patient was symptom free. Perimetric study disclosed an upper left homonymous defect.

Comment: In this case, as in the previous one, primary healing was not anticipated, but the temporary presence of the implant prevented cerebral fungus and aided the patient's recovery.

Case 7—A man, aged 36, was admitted to the hospital July 28, 1945. July 10 he had chills, fever, and generalized aching, and was treated for "grippe." July 14 he had developed headache, tingling, and weakness of the left arm, and an impairment of the left field of vision. He was admitted to another hospital July 18, where the spinal fluid pressure was found to be 15 mm. of mercury. Fluid contained 690 cells, 60 per cent of which were polymorphonuclear. Temperature was 102.2 F. He was treated with penicillin and sulfadiazine; fever subsided, but the hemianopsia and weakness of the left arm persisted, with extension of this weakness to the left leg.

On admission the patient had mild papilledema, a complete left homonymous hemianopsia, a pronounced left hemiparesis involving face, arm, and leg, with astereognosis and loss of sense of position. Spinal fluid pressure was 500 mm. of water. Spinal fluid contained no cells. Diagnosis was right temporoparietal abscess from some undetermined focus, probably metastatic from the lungs.

Due to comparatively recent formation of the abscess, surgical intervention was delayed for a time in order to obtain more thorough encapsulation. Patient was placed on 30,000 units of penicillin intramuscularly every three hours, and oral sulfadiazine.

August 8, a right temporoparietal craniotomy was performed. A cannula located the abscess in the parietal lobe considerably higher than was anticipated. The scalp incision was carried higher and the bony opening extended upward with a rongeur to expose the abscess site. Cortex and abscess wall were incised, pus removed, and the abscess wall excised. The abscess appeared to originate in the center of the parietal lobe and had no dural attachment. After removal the large bony opening was covered with a perforated tantalum implant. Dura was left widely open, 30,000 units of penicillin was introduced beneath the implant, and the wound was closed. Examination of the

pus disclosed *Streptococcus mitior* in pure culture. Penicillin was continued intramuscularly and sulfadiazine orally. For three days 30,000 units of penicillin was injected beneath the scalp daily. Patient remained afebrile following operation and became more alert, but on the fifth postoperative day the left hemiparesis became complete. Wound healed by primary union, and the patient was discharged August 26. He was readmitted August 31, with chills, headache, stiff neck, and a temperature of 101 F. Spinal fluid, normal just prior to discharge, was cloudy and pressure was 350 mm. of water. This fluid contained 5000 polymorphonuclears. The culture was sterile. Patient was placed on 50,000 units of penicillin, given intramuscularly every three hours, and sulfadiazine given orally. Daily spinal punctures were performed and fluid remained cloudy until September 11. September 19, the patient still complained of headaches. Suspecting a recurrent brain abscess, I introduced a needle through one of the tantalum plate perforations, but no pus was encountered. September 25 an encephalogram was made. Films showed a slight shift of the ventricular system to the left side. Patient continued to complain of headaches, and there was no improvement of the left hemiplegia.

October 5 the previous scalp flap was reflected and the tantalum implant removed. There was neither fluid nor any evidence of infection about the implant. Part of the exposed brain was covered by the original dura. The upper portion of the exposed brain was covered merely by thin, transparent, newly formed dura. Multiple punctures with a brain cannula in the parietal, frontal, occipital, and temporal lobes failed to disclose an abscess. The tantalum implant was replaced and the scalp closed. Patient's convalescence was satisfactory and his headaches relieved. He remained afebrile and the wound healed by primary union. The patient was discharged October 13.

He was readmitted October 25, 1945, with recurrence of headache and fever. Once more a needle was introduced through one of the perforations in the tantalum implant and this time an abscess was encountered in the posterior inferior portion of the occipital lobe. Seventeen cubic centimeters of pus was removed, and 30,000 units of penicillin was injected into the cavity. During the operation the patient was given 1,000,000 units of penicillin intravenously, and from then until his death he received 400,000 units of penicillin daily, either intramuscularly or intravenously. Sulfadiazine was given orally or intravenously daily, the blood level varying between 4.0 and 20.5 mg. per 100 cc.

The patient did not improve, and it was apparent by this time that he had multiple abscesses in the right cerebral hemisphere. On October 31, 1945, it was decided to remove the right cerebral hemisphere in an effort to preserve life. On reflection of the scalp, the tantalum implant was found in good condition with no evidence of infection about it. The implant was removed, the bony opening enlarged, and the hemisphere removed. A firm mass was palpable in the tip of the temporal lobe but no pus was spilled. The dura was not closed. The skull defect was repaired by a perforated tantalum implant measuring 5 x 6 inches, and the wound was closed. A rubber tissue drain was inserted through a stab wound, down to the tantalum implant. This drain was removed in a few days and replaced by daily aspiration of the cavity, followed by the injection of 50,000 units of penicillin. The wound healed readily but the patient's condition gradually failed and he expired on November 20, 1945, of intracranial sepsis due to *Alcaligenes faecalis*. Necropsy was not obtained. Examination of the specimen removed showed a chronic abscess in the tip of the temporal lobe and another in the posterior portion of the occipital lobe. There was no recurrence of the parietal lobe abscess.

Comment: The significant feature of this case is that at subsequent operations fifty-eight and eighty-four days after the original operation,

Case	Age	Sex	Date of Cranio-plasty	Primary Focus	Method of Invasion	Location of Abscess	Bone Involvement	Surgical Procedure*
1	17	M.	6/27/44	Frontal sinusitis and osteomyelitis of frontal bone	Metastasis or by thrombophlebitis of sagittal sinus	Right parieto-occipital (multiple subcortical and subdural)	Previous osteomyelitis of frontal bone; none at operative site	Piecemeal excision of abscesses by electro-surgery; no drainage
2	33	F.	2/14/45	Acute right otitis media	Direct extension	Right temporal (subcortical)	Stalk adherent to dura over petrous bone	Complete excision of abscess; no drainage
3	6	M.	2/19/45	Acute right orbital abscess	Direct extension	Right frontal (subcortical)	Stalk adherent to dura over orbit roof	Complete excision of abscess; no drainage
4	17	M.	5/14/45	Acute frontal sinusitis and osteomyelitis	Direct extension	Left frontal (subcortical)	Frontal osteomyelitis and periosteal	Infected frontal bone excised; abscess drained through indwelling cannula
5	49	M.	5/15/45	Chronic mastoiditis left	Direct extension	Left temporal (subcortical and epidural)	Chronic mastoiditis; stalk adherent to dura over mastoid	Complete excision of abscess; postoperative irrigation through needles beneath scalp
6	15	M.	8/10/45	Chronic mastoiditis right	Direct extension	Right temporal (subcortical)	Chronic mastoiditis with cholesteatoma; stalk adherent to dura over petrous bone	Complete excision of abscess; no drainage
7	36	M.	8/8/45	Pneumonia	Metastasis	Right parietal (subcortical); temporal and occipital (subcortical—found at second operation)	None	Complete excision of abscess; no drainage
8	23	F.	10/19/45	Draining sinus in popliteal space—probably tuberculous	Metastasis	Left occipital (subcortical)	None	Complete excision

* In each case the cranial defect was closed by a perforated tantalum implant fashioned at the operating table and fastened to the outer table of the skull by means of 2 tantalum screws. The size of the implants varied from 6 x 6 cm. to 9 x 12 cm.

USE OF TANTALUM

Pus Culture	Sulfonilimide Placed in Wound at Operation Grams	Postoperative Sulfadiazine Grams Daily	Placed in Wound at Operation Units	PENICILLIN Injected Into Operation Site Units	Intra-muscular Units	Wound Healing	Result
Streptococcus anaerobius	None	None	10,000	10,000 every 4 hr. 12 times; then twice daily for 14 days; 10,000 intraspinally every 12 hr. 4 times	10,000 every 4 hr. for 16 days	Per primam	Alive and well 18 mo. postoperative
Diplococcus pneumoniae type I	5	4 for 16 days	25,000	20,000 every 12 hr. 4 times	15,000 every 3 hr. for 16 days	Per primam	Alive and well 11 mo. postoperative
Streptococcus salivarius	5	4 for 10 days	15,000	15,000 daily for 3 days	15,000 every 3 hr. for 10 days	Per primam	Death on 39th post-operative day from recurrent brain abscess; tantalum implant not involved
Alcaligenes faecalis and Streptococcus faecalis	5	4-6 for 27 days	None	Continuous irrigation of abscess cavity with 100/cc. saline solution for 4 days	15,000 every 3 hr. for 27 days	Per primam	Alive and well 8 mo. postoperative
Streptococcus anaerobius and Proteus vulgaris	5	4-6 for 41 days	10,000	Continuous irrigation of operation site with 100/cc. saline solution for 5 days	20,000 every 3 hr. for 34 days	Abscess formed about implant; drained 5-31-45; mastoidectomy 5-31-45; implant removed 6-15-45; drainage ceased 10-2-45	Alive and well 8 mo. postoperative
Bacillus coli and Staphylococcus albus	5	4 for 45 days	30,000	25,000 daily for 10 days	30,000 every 3 hr. for 25 days	Abscess formed about implant; drained 8-24-45; mastoidectomy 9-11-45; implant removed 9-19-45; drainage ceased 10-27-45	Alive and well 5 mo. postoperative
Streptococcus mitior	None	6 for 13 days	30,000	30,000 daily for 3 days	30,000 every 3 hr. for 16 days	Per primam	Death 3½ mo. postoperative due to other metastatic brain abscesses; implant was not involved
Sterile	5	4-6 for 9 days	20,000	None	30,000 every 3 hr. for 9 days	Per primam	Alive and well 3 mo. postoperative

the implant was found to be in good condition and free of infection. This occurred despite the fact that two previously undiscovered abscesses were still present in the brain.

Case 8—A colored woman, aged 23, was admitted to the hospital October 17, 1945, with a complaint of headache, loss of vision, and impairment of memory. The symptoms began four months previously, following childbirth. The only significant findings were a severe papilledema, a complete right homonymous hemianopsia, and a healed scar from a previous chronic draining sinus in the left popliteal space. The spinal fluid pressure was 530 mm. of water and it contained no cells. The clinical diagnosis was left occipital lobe tumor or perhaps tuberculoma.

October 19, 1945, a left occipital craniotomy was performed. The dura was thickened and adherent to the cortex near the sagittal sinus. Beneath the cortex a large firm nodular mass could be felt. A biopsy of the mass resulted in the discharge of 2 or 3 ounces of thick pus. The large abscess was then freed from the falx and removed by blunt dissection with the attached dura. The cavity was irrigated with saline, the bone flap discarded, and the bony defect covered with a perforated tantalum implant. The dura was not closed. One hundred thousand units of penicillin was given intravenously and 20,000 units was placed in the brain cavity. Five grams of sulfanilamide was placed on the outer surface of the implant, and the scalp was closed.

For nine days following operation the patient was given 30,000 units of penicillin intramuscularly every three hours and 1 Gm. of sulfadiazine orally four to six times daily. Convalescence was satisfactory, and she was discharged from the hospital October 30, 1945.

The microscopic diagnosis on the abscess wall was tuberculoma. Culture of the pus was sterile, and guinea pig inoculation of the pus was negative for tuberculosis. In view of the gross and microscopic appearance this is classified as a tuberculous abscess.

The patient was seen January 18, 1945. She appeared to be in excellent health. The scalp was well healed but slightly fluctuant over the site of the implant. Fluid aspirated from this area was clear and colorless. It contained 60 lymphocytes and total protein content was 192 mg. per cent. The culture was sterile.

Comment: Perhaps this case should not be included in a series of infected cases since the culture of the pus was sterile and guinea pig inoculations were negative. Microscopically the abscess wall had the typical appearance of a tuberculoma except that tubercle bacilli could not be identified in it. It appears possible that this wound will subsequently break down, but even though it does, the patient has certainly profited by the protection which the implant has afforded.*†

SUMMARY

Tantalum implants were used to close skull defects in 8 infected cases (7 brain abscesses and 1 acute osteomyelitis of the skull). Primary healing of the wound occurred in 6 of the 8 cases. The wounds became infected in 2 patients in whom the implant was contiguous to chronically

* As this article was going to press on Feb. 14, 1946, the injected guinea pig was found to be sick. At autopsy tuberculosis was disclosed.

† The author wishes to express appreciation to Mr. A. Reich of the Department of Bacteriology for help and suggestions in the study of these cases.

infected mastoid and draining ear canal. The implants in these 2 cases were removed four and six weeks later. These patients were benefited by the temporary presence of the implant.

Two of the patients died, one of a recurrence of the brain abscess and the other of metastatic abscesses in other parts of the brain. In neither case was the presence of the implant a factor in the unfavorable outcome.

The presence of tantalum did not delay healing, but rather the healing process was aided by splinting and immobilization of the wound which the implant provided. These results attest to the passivity of tantalum implants and justify the continued use of the material in such cases.

Seven cases of brain abscess were treated by a new method, namely radical excision of the abscess and closure of the skull defect by a tantalum implant and closure of the scalp without drainage. The patients were then treated with penicillin and sulfadiazine. The results in these few cases justify the continued use of the method.

The efficacy of present day antibiotics demands a re-evaluation of the surgical principle that foreign material should not be used to repair a bone defect in an infected wound.

REFERENCES

1. Burke, G. L.: Corrosion of metals in tissues; and introduction to tantalum. *Canad. M.A.J.* **43**:125-128 (Aug.) 1940.
2. Carney, H. M.: Experimental study with tantalum. *Proc. Soc. Exper. Biol. and Med.* **51**:147-148 (Oct.) 1942.
3. Fulcher, O. H.: Tantalum as metallic implant to repair cranial defects; preliminary report. *J.A.M.A.* **121**:931-933 (Mar. 20) 1943.
4. Pudenz, R. H.: Use of tantalum clips for hemostasis in neurosurgery. *Surgery* **12**:791-794 (Nov.) 1942.
5. Idem: Repair of cranial defects with tantalum; experimental study. *J.A.M.A.* **121**:478-481 (Feb. 13) 1943.
6. Pudenz, R. H., and Odom, G. L.: Meningocerebral adhesions: experimental study of effect of human amniotic membrane, amnioplastin, beef allantoic membrane, corgile membrane, tantalum foil, and polyvinyl alcohol films. *Surgery* **12**:318-344 (Aug.) 1942.
7. Spurling, R. G.: Symposium on war surgery; use of tantalum wire and foil in repair of peripheral nerves. *S. Clin. North America* **23**:1491-1504 (Dec.) 1943.
8. Woodhall, B., and Spurling, R. G.: Tantalum cranioplasty for war wounds of the skull. *Ann. Surg.* **121**:649-671 (May) 1945.
9. Mayfield, F. H., and Levitch, L. A.: Repair of cranial defects with tantalum. *Am. J. Surg.* **67**:319-322 (Feb.) 1945.
10. Hemberger, A. J., Whitcomb, B. B., and Woodhall, B.: The technique of tantalum plating of skull defects. *J. Neurosurg.* **2**:21-25 (Jan.) 1945.
11. Robertson, R. C. L.: Repair of cranial defects with tantalum. *J. Neurosurg.* **1**:227-236 (July) 1944.
12. Gardner, W. J.: Tantalum in immediate repair of traumatic skull defects; method of immobilizing wounded brain. *U. S. Nav. M. Bull.* **43**:1100-1106 (Dec.) 1944.
13. Idem: Closure of defects of the skull with tantalum. *Surg., Gynec. and Obst.* **80**:303-312 (Mar.) 1945.
14. Carmichael, F. A., Jr.: The reduction of hernia cerebri by tantalum cranioplasty; a preliminary report. *J. Neurosurg.* **2**:379-383 (Sept.) 1945.