

REFERENCES

1. Drinker, C. K., and Field, M. E.: *Lymphatics, Lymph and Tissue Fluid* (Baltimore: Williams and Wilkins, 1933).
2. MacCallum, cited by Bodanski, Meyer: *Introduction to Physiological Chemistry*, ed. 4 (New York: John Wiley and Son, 1938).
3. Starling, E. H.: *Fluids of the Body* (Chicago: W. T. Keener and Co., 1909).
4. Corcoran, A. C., and Page, I. H.: Unpublished observations.
5. Stead, E. A., Jr., and Warren, J. V.: Protein content of extracellular fluid in normal subjects after venous congestion and in patients with cardiac failure, anoxemia and fever. *J. Clin. Investigation* **23**:283-287 (March) 1944.
6. Gamble, J. L.: Extracellular fluid; extracellular fluid and its vicissitudes. *Bull. Johns Hopkins Hosp.* **61**:151-173 (Sept.) 1937.
7. Butler, A. M., and Talbot, N. B.: Medical progress; parenteral fluid therapy; estimation of losses incident to starvation and dehydration with acidosis or alkalosis and provision of repair therapy. *New England J. Med.* **231**:621-628 (Nov. 2) 1944.
8. Merrill, A. J., Warren, J. V., and Stead, E. A., Jr.: Renal blood flow in congestive heart failure. Presented at Am. Fed. Clin. Research, Chicago, Nov. 2, 1944.

CARCINOMA COMPLICATING ULCERATIVE COLITIS

Report of Two Cases

R. J. F. RENSHAW, M.D., AND T. S. BROWNELL, M.D.

Because the complication seemed to be uncommon, we have reviewed our experience with carcinoma complicating ulcerative colitis. Between 1934 and 1943 one of us saw 2 cases of carcinoma in 336 cases of ulcerative colitis. This was an incidence of 0.59 per cent. During the same period 1608 cases of carcinoma of the colon were seen at the Cleveland Clinic.

Because both patients herein reported were under 30 years of age, our attention was directed to this age group. One per cent (17 cases) of all cases of carcinoma of the colon and 38 per cent (128 cases) of all cases of ulcerative colitis occurred in persons under 30. In this same age group the incidence of carcinoma of the colon with chronic ulcerative colitis (1.5 per cent) was slightly higher than the incidence without ulcerative colitis (1 per cent).

Ewing¹ considered it significant that carcinoma rarely occurred in ulcerative colitis. Matzner and Schaefer² reported 1 case of carcinoma complicating ulcerative colitis. The patient was a 29 year old man. Yeomans³ reported 7 cases of malignant neoplasm developing in rectal adenoma, 1 of which occurred with ulcerative colitis. This patient was a 33 year old woman. Hurst⁴ stated that an adenomatous polyp might become malignant and that carcinoma might complicate ulcerative colitis, but that most malignant adenomas were not secondary to or associated with colitis. Swinton and Warren⁵ stated that they had not observed progression of polypoid changes in ulcerative colitis to malignant disease. On the other hand, Ganshorn⁶ demonstrated a greater frequency of carcinoma in the presence of adenomatous hyperplasia of the

mucous membrane. In 217 patients of all ages with ulcerative colitis Streicher⁷ found an incidence of carcinoma of 1.2 per cent. Bockus⁸ observed 3 cases in approximately 200, an incidence of 1.5 per cent.

A higher incidence of carcinoma has been found by Bargaen and his colleagues, who have had extensive experience. Since the beginning of the study Bargaen has seen 54 cases of carcinoma complicating ulcerative colitis.^{9, 10, 11, 12} He also advised one of us that since his last report⁹ he has seen six additional cases. He further believes that carcinoma complicating ulcerative colitis is occurring with increasing frequency.¹³ In 1929 he reported an incidence of 2.5 per cent in 693 cases of ulcerative colitis,¹⁰ and in 1938 a 3.2 per cent incidence in 817 cases.¹¹

Jackman, Bargaen, and Helmholtz¹⁴ in a study of 95 children with ulcerative colitis reported the highest incidence of carcinoma, 6.3 per cent. The reason for this unusually high figure is not clear to us. According to Bockus⁸ these statistics might indicate that ulcerative colitis predisposed to the development of carcinoma and that conceivably adenomatosis was the initial lesion in some of the children. Bargaen¹² ventured the opinion that the severely destructive process of colitis might exhaust the tissues' reparative ability and precipitate a wild growth of cells. This theory applied to children in an active growth phase might explain the higher incidence of carcinoma complicating ulcerative colitis.

Polyposis is generally conceded to be the most common complication of ulcerative colitis (10 per cent). It is a pseudopolyposis consisting of mucous membrane tags after healing has taken place or of islets of mucous membrane between areas of ulceration. As shown by Coffey and Bargaen¹⁵ one must clearly differentiate between polyposis and adenomatosis. They found a 62.5 per cent incidence of carcinoma in adenomatosis, whereas in multiple polyposis complicating ulcerative colitis the incidence was only 25 per cent, which is higher than most workers report. It is generally believed that the polyposis of ulcerative colitis is not related to adenomatosis and shows no greater tendency to undergo malignant change than normal mucosa.

CASE REPORTS

Case 1—A white man, aged 22, was seen in the clinic in November 1935. The previous April he had an appendectomy for an attack of lower right quadrant pain. Shortly thereafter he had diarrhea of eight to ten stools a day and an afternoon fever of 102 to 103 F.

Examination of the rectal mucosa revealed changes typical of chronic ulcerative colitis. Occult blood and pus but no parasites were found in a stool examination. Stool cultures showed nonhemolytic streptococci, *Staphylococcus albus*, and gram-negative bacilli. Roentgenologic examination revealed that ulcerative colitis involved the entire colon. The erythrocyte count was 4,730,000, leukocyte count 11,000, and hemoglobin 12.0 Gm. per 100 ml. blood.

The patient, who was seen in the clinic only a few times in the succeeding nine year period, received various types of treatment elsewhere. In October 1944 he returned complaining of sharp, stabbing pains across the upper abdomen and for the preceding five weeks of an increase in the number of stools daily.

In the right upper abdominal quadrant was a palpable, poorly defined, firm, smooth mass, which did not move with respiration. By proctoscopic examination the rectal mucosa was found to be granular. It bled only slightly when swabbed. At the level of the prostate gland was a localized area of pseudopolyposis. Roentgenologic examination showed that ulcerative colitis involved the entire colon. A large irregular filling defect involved the hepatic flexure and proximal colon (fig. 1).

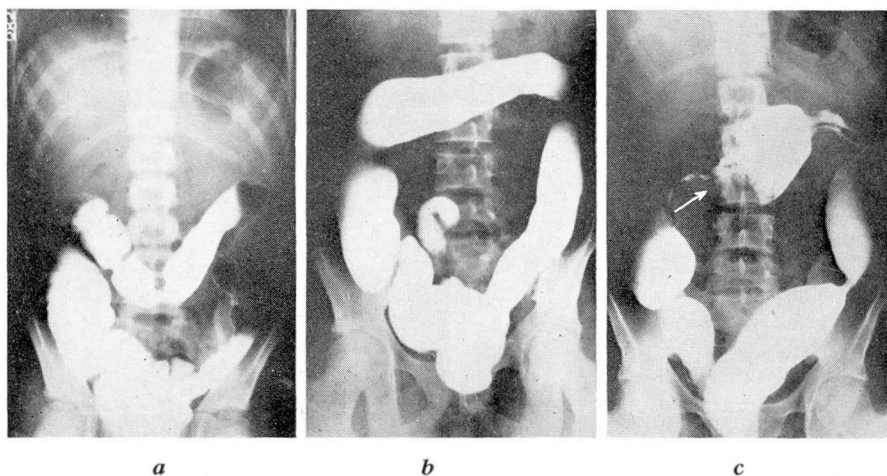


FIG. 1 (Case 1)—(a) Appearance of colon in 1935 when the patient was first seen in Clinic. (b) Appearance of colon in 1940. (c) Appearance of colon in 1944. Filling defect and obstruction at site of arrow.

A right colectomy was done. Pathologic examination disclosed an ulcerated, polypoid, mucinous adenocarcinoma of the hepatic flexure and ascending colon. There was invasion of the colon wall with direct extension into paracolic areolar tissue, involvement of lymphatics and venules, and metastasis to regional lymph nodes. There was also focal, acute, ulcerative, widespread, chronic inflammation of the ileum, cecum, and ascending and transverse colon, with atypical polypoid hyperplasia and multiple polyps.

The patient died at home a few months later. No autopsy was performed, and the immediate cause of death could not be ascertained.

Case 2—A white housewife, aged 27, was seen in the clinic in February 1941. During the preceding nine years she had three to four loose bloody stools daily, and a diagnosis of chronic ulcerative colitis was made in a university hospital. Two or three weeks before admission to the clinic she had cramping pains, soreness of the abdomen, borborygmi, bloating, and fever.

The patient was poorly nourished and toxic. The temperature was 100 F. The abdomen was distended, and the superficial veins were dilated. A visible and palpable mass filling the epigastrium and right upper quadrant and extending to the iliac crest on the right was thought to be a nodular, enlarged liver. A fibrous stricture of the rectum was found about three inches from the anus, beyond which the proctoscope could not be inserted. The mucous membrane between the anus and the fibrous band was edema-

tous and had the typical appearance of severe advanced ulcerative colitis. There were multiple ulcers and a profuse mucopurulent discharge. The mucosa was friable and granular and bled easily.

Laboratory examination revealed 2 plus amounts of albumin in the urine, 5,800,000 erythrocytes, 14.9 Gm. hemoglobin per 100 ml. blood, and 17,500 leukocytes with 70 per cent polymorphonuclear neutrophils and 30 per cent lymphocytes. The icterus index was 13. Wassermann and Kahn reactions of the blood were negative. No parasites were found in the stools.

Roentgenologic examination of the colon showed pronounced narrowing of the rectum just proximal to the anus in the region of the inflammatory stricture seen through the proctoscope. In the midtransverse colon an obstructing lesion was demonstrated (fig. 2).

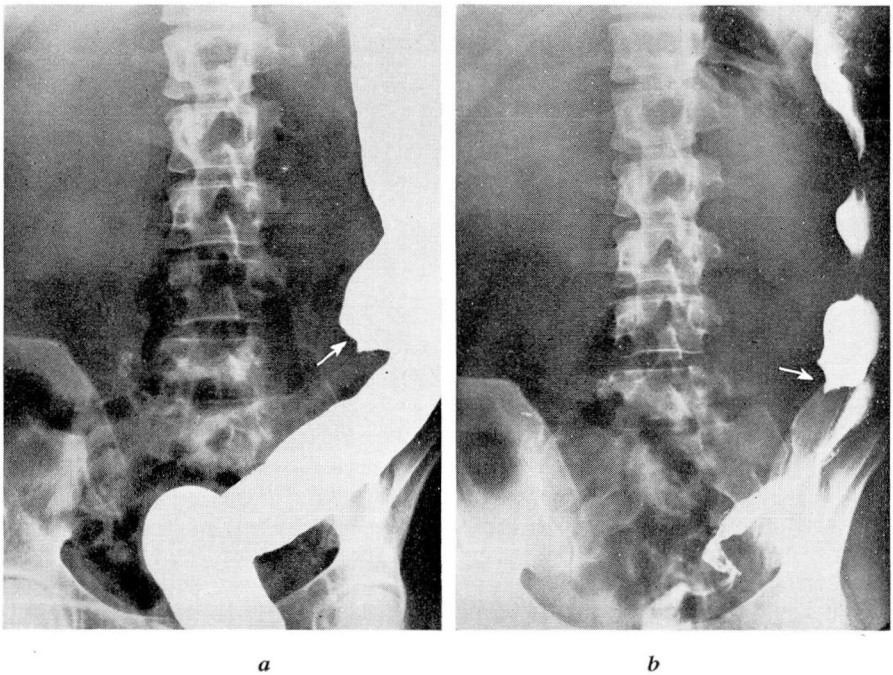


FIG. 2 (Case 2)—(a) Obstructing lesion in transverse colon beyond which barium enema could not be forced. (b) Postevacuation film. Large liver extends almost to iliac crest.

On the basis of these findings a diagnosis was made of ulcerative colitis and carcinoma of the transverse colon with metastasis to the liver. Confirmation of this diagnosis was not possible by microscopic section, but clinically there was no doubt as to the presence of a malignant neoplasm.

The patient refused peritoneoscopy and exploratory laparotomy and was discharged on medical management. She died at home three weeks later.

SUMMARY

Carcinoma of the colon complicating chronic ulcerative colitis as observed in the Cleveland Clinic is uncommon in adults. Only 2 cases

were encountered in a nine year period, which was an incidence of 0.59 per cent of all cases of chronic ulcerative colitis and of 1.5 per cent of cases occurring in patients under 30 years of age.

REFERENCES

1. Ewing, J.: *Neoplastic Diseases*, ed. 4 (Philadelphia: W. B. Saunders Co., 1934) pp. 710-717.
2. Matzner, M. J., and Schaefer, G.: Chronic ulcerative colitis complicated by carcinoma. *Rev. Gastroenterol.* **6**:422-427 (Sept.-Oct.) 1939.
3. Yeomans, F. C.: Carcinomatous degeneration of rectal adenomas: report of seven cases. *J.A.M.A.* **89**:852-854 (Sept. 10) 1927.
4. Hurst, A. F.: Prognosis of ulcerative colitis. *Lancet* **2**:1194-1196 (Nov. 23) 1935.
5. Swinton, M. W., and Warren, S.: Polyps of the colon and rectum and their relation to malignancy. *J.A.M.A.* **113**:1927-1933 (Nov. 25) 1939.
6. Ganshorn, cited by Sauer and Bergen.⁹
7. Streicher, M. H.: Clinical course of chronic ulcerative colitis (based on 7662 proctoscopy examinations). *Am. J. Digest. Dis.* **5**:361-363 (Aug.) 1938.
8. Bockus, H. L.: *Gastro-Enterology* (Philadelphia: W. B. Saunders Co., 1944) vol. 2, p. 593.
9. Bergen, J. A., and Sauer, W. G.: Association of chronic ulcerative colitis and carcinoma. *Clinics* **3**:516-534, 1944.
10. Bergen, J. A.: Complications and sequelae of chronic ulcerative colitis. *Ann. Int. Med.* **3**:335-352 (Oct.) 1929.
11. Jackman, R. J., Bergen, J. A., and Kerr, J. G.: Studies on the life histories of patients with chronic ulcerative colitis (thrombo-ulcerative colitis) with some suggestions for treatment. *Ann. Int. Med.* **12**:339-352 (Sept.) 1938.
12. Sauer, W. G., and Bergen, J. A.: Chronic ulcerative colitis followed by carcinoma; report of 26 cases. *Proc. Staff Meet., Mayo Clinic* **19**:311-315 (June 14) 1944.
13. Bergen, J. A.: Personal communication to the author.
14. Jackman, R. J., Bergen, J. A., and Helmholtz, H. F.: Life history of 95 children with chronic ulcerative colitis; statistical study based on comparison with whole group of 817 patients. *Am. J. Dis. Child.* **59**:459-467 (Mar.) 1940.
15. Coffey, R. J., and Bergen, J. A.: Intestinal polyps: Pathogenesis and relation to malignancy. *Surg., Gynec. & Obst.* **69**: 136-145, (Aug.) 1939.

MODIFICATIONS IN THE ROURKE-ERNSTENE SEDIMENTATION RATE METHOD

L. W. DIGGS, M.D.

The Rourke-Ernstene method¹ for determination of sedimentation rate measures the sinking velocity of erythrocytes during the period of most rapid fall. This method is considered to be more accurate than those that utilize a single one hour reading,² such as the Wintrobe, Cutler, and Westergren methods. Other advantages of the method are the following: A small volume of blood (1.5 ml.) is required, the volume of packed red blood cells can be determined, and correction for anemia