

SUBUNGUAL MELANOMA IN NEGROES

JAMES A. DICKSON, M.D., AND T. F. JARMAN, M.D.

Reprinted by special permission from ANNALS OF SURGERY, 95:450-473, March, 1932.

Melanotic tumors of all types are very rare in the Negro. Adair, Pack, and Nicholson¹ in a review of the literature on this subject found fourteen reported cases up to 1926. One of three cases of subungual melanoma which these authors observed at Memorial Hospital occurred in a Negro. In 1927 Bauer² reported two cases of melanotic tumors occurring in Negroes, one of which was a subungual melanoma. We can now add a further case to those already reported.

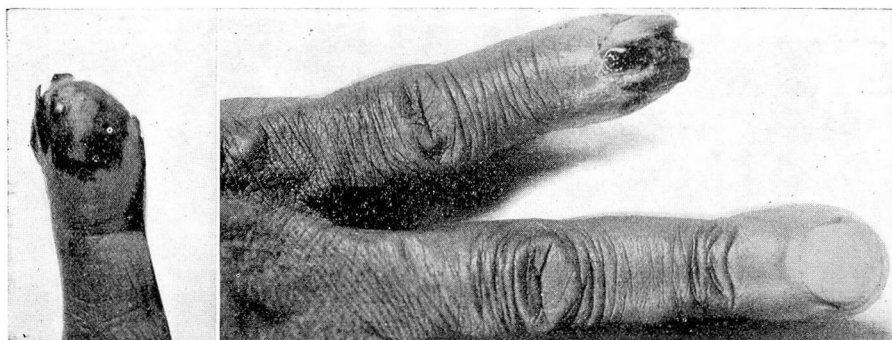


Fig. 1. Photograph of fifth finger of left hand, showing subungual melanoma.

A Negress, seventy-three years of age, came to the Cleveland Clinic complaining of discoloration of the fifth finger of the left hand. The following history was obtained: For twenty years she had had a "black spot" on the nail of the fifth finger of the left hand. This spot grew gradually larger and another developed, so that there were two large discolored areas on the nail, both quite black in color. This condition had remained constant for the past fifteen years, during which time the area of discoloration had not increased in size. Six months previous to the admission of the patient, the nail split, assuming a bifid character. Up to that time the nail had been normal in shape and configuration (Fig. 1).

Physical examination of the patient revealed nothing abnormal apart from the black discoloration of the fifth finger of the left hand, including the nail which was bifid due to a splitting down its centre as far as the nail bed. Pus could be evacuated from the central split

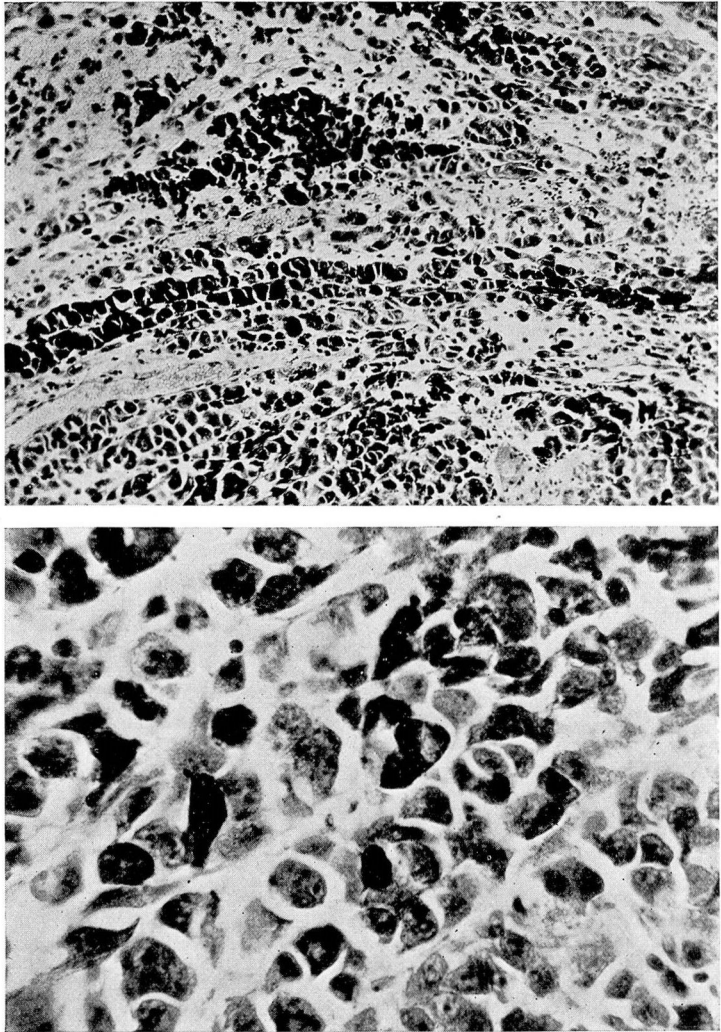


Fig. 2. (A) Photomicrograph of subungual melanoma (x 150). (B) High-power photomicrograph of same area of tissue as shown in A (x 600).

down the nail. The palmar aspect of the tip of the finger presented an area of dark, gangrenous-appearing skin. No enlarged regional lymph-nodes could be detected.

Clinically, the lesion was thought to be an infected, melanotic, pigmented tumor, the exact pathological nature of which could not be determined. Microscopical examination of a small piece of tissue from the nail bed showed that the tumor was a subungual melanoma of low-grade malignancy.

The finger was amputated at the metacarpo-phalangeal joint and the head of the metacarpal bone was removed. The wound healed by first intention.

The following is the report of the microscopical examination of the removed tissue:

"Section of tissue through the nail bed shows thickened epidermis covered by a heavy layer of keratohyaline material in the region of the base of the nail. In the region of the tip, the epithelium is destroyed, the tissue is ulcerated, and in the deeper layers there is a large quantity of very cellular tissue rich in melanin pigment. In some areas the quantity of melanin pigment is large and the number of actively growing tumor cells is small. This is particularly true of the area near the base of the nail. Near the tip of the finger the tumor cells predominate over the pigment. The vast majority of the cells, however, contain fine, granular, dark-brown pigment in the cytoplasm. The tumor cells are quite large; some are multinucleated. Mitotic figures are rare." (Fig. 2.)

Second Pathological Report. "Longitudinal section through the distal phalanx, including the nail, soft tissues and bone — which has been decalcified — shows keratosis of the nail bed and ulceration of the tip of the finger. Considerable diffuse inflammatory reaction is present in the soft tissues. There is no involvement of bone. A large amount of melanin pigment may be observed below the epidermis under the tip of the nail. The melanin-forming cells show very little evidence of active growth."

The pathological diagnosis was *subungual melanoma* of low-grade malignancy. The patient was instructed to return to the clinic at frequent intervals for examination but she neglected to do so. She was visited July 20, 1931, ten and a half months following the removal of the finger. The amputation scar was found to be in perfect condition and there was no evidence of any neoplastic process.

The left epitrochlear and axillary lymph glands, however, were definitely enlarged and hard, but not fixed. The patient was in excellent condition and had not noticed the presence of the nodules in the left epitrochlear and axillary regions.

BIBLIOGRAPHY

- 1 Adair, Frank E., and Pack, George T., with the assistance of Mary E. Nicholson: *Mélanomes sous-ungueaux et leur diagnostic différentiel. À propos de quatre cas.* Laboratory studies ii and Clinical studies vii, from the Memorial Hospital, New York City, 1930.
- 2 Bauer, John T.: Malignant Melanotic Tumors in the Negro. *Arch. of Path. and Lab. Med.*, 3:151, 1927.